

# Central Nervous System

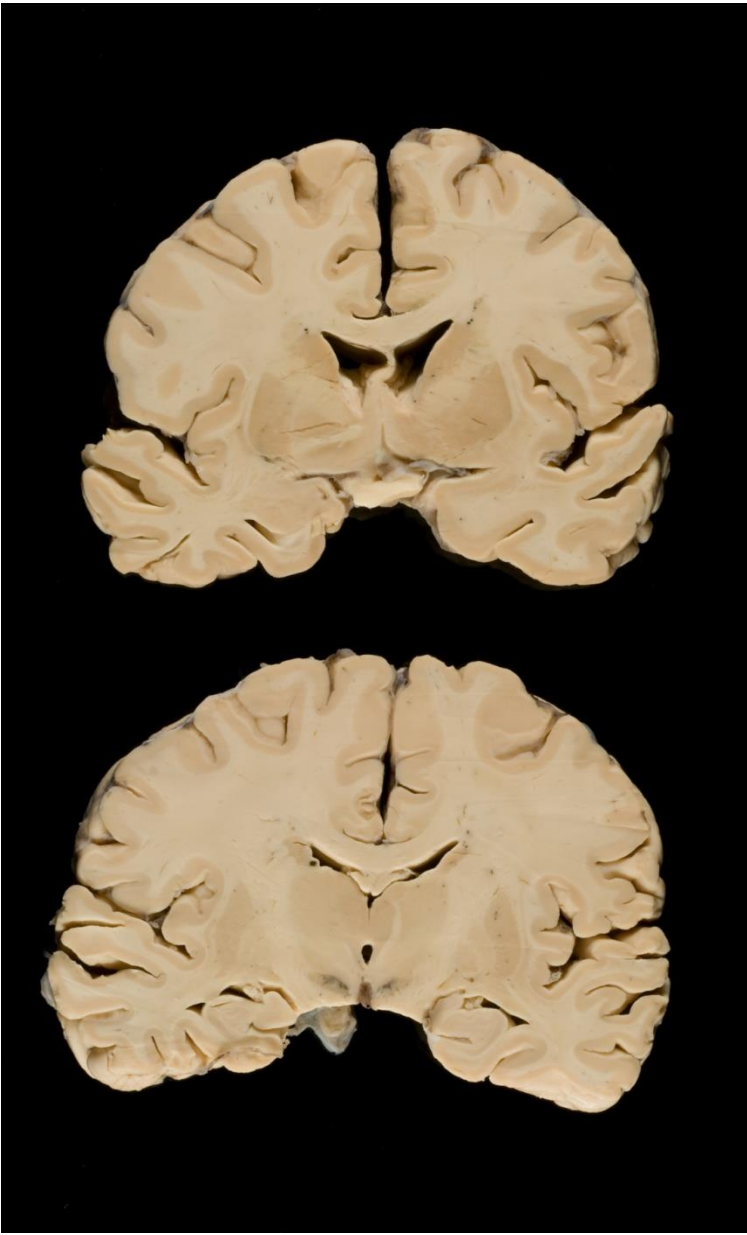Roadshow

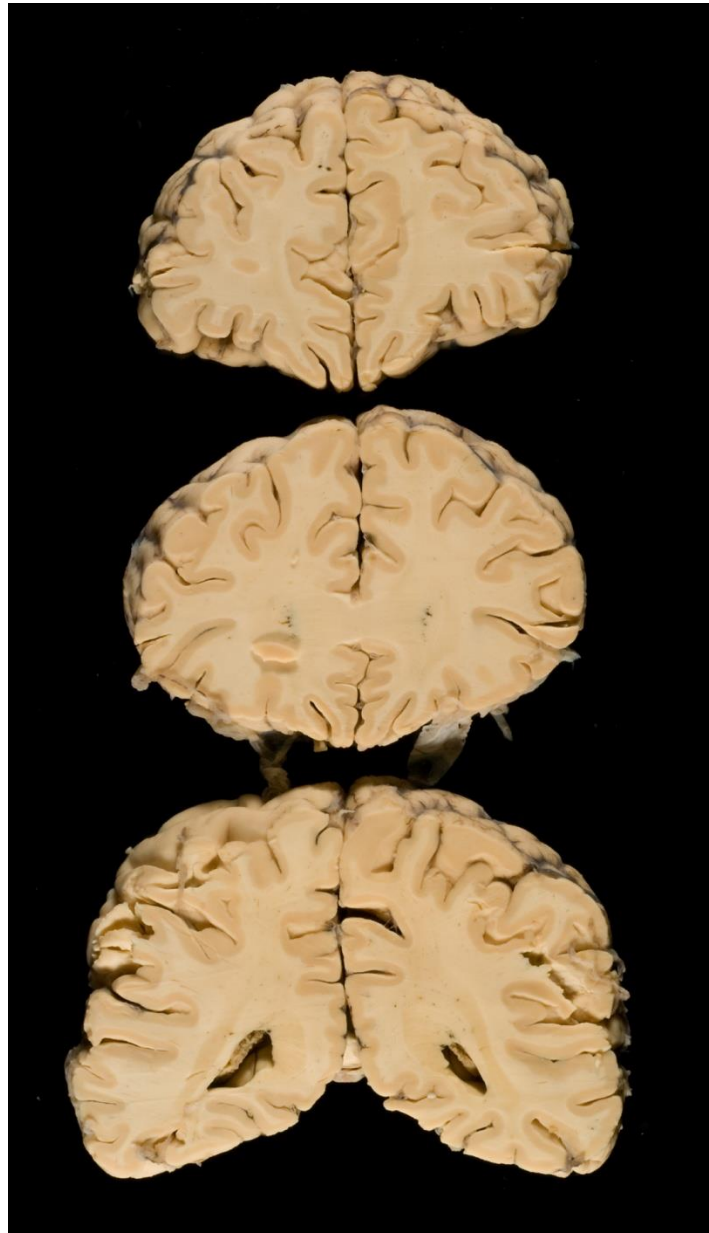
**These specimens are fixed but not mounted.**

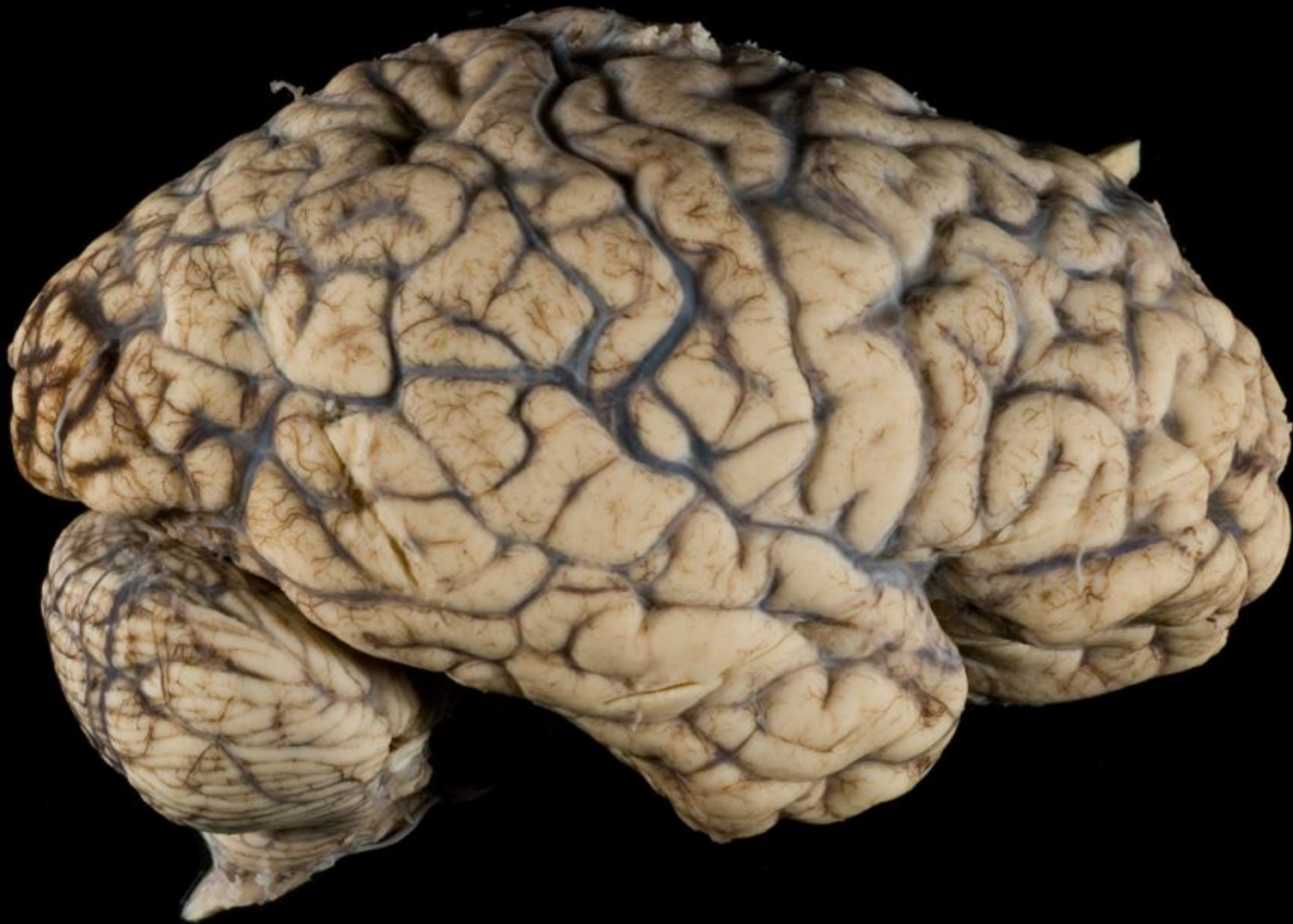Several specimens from patients without neuropathology are displayed.

Specimens have been sectioned in different planes; coronal, mid-sagittal and horizontal.

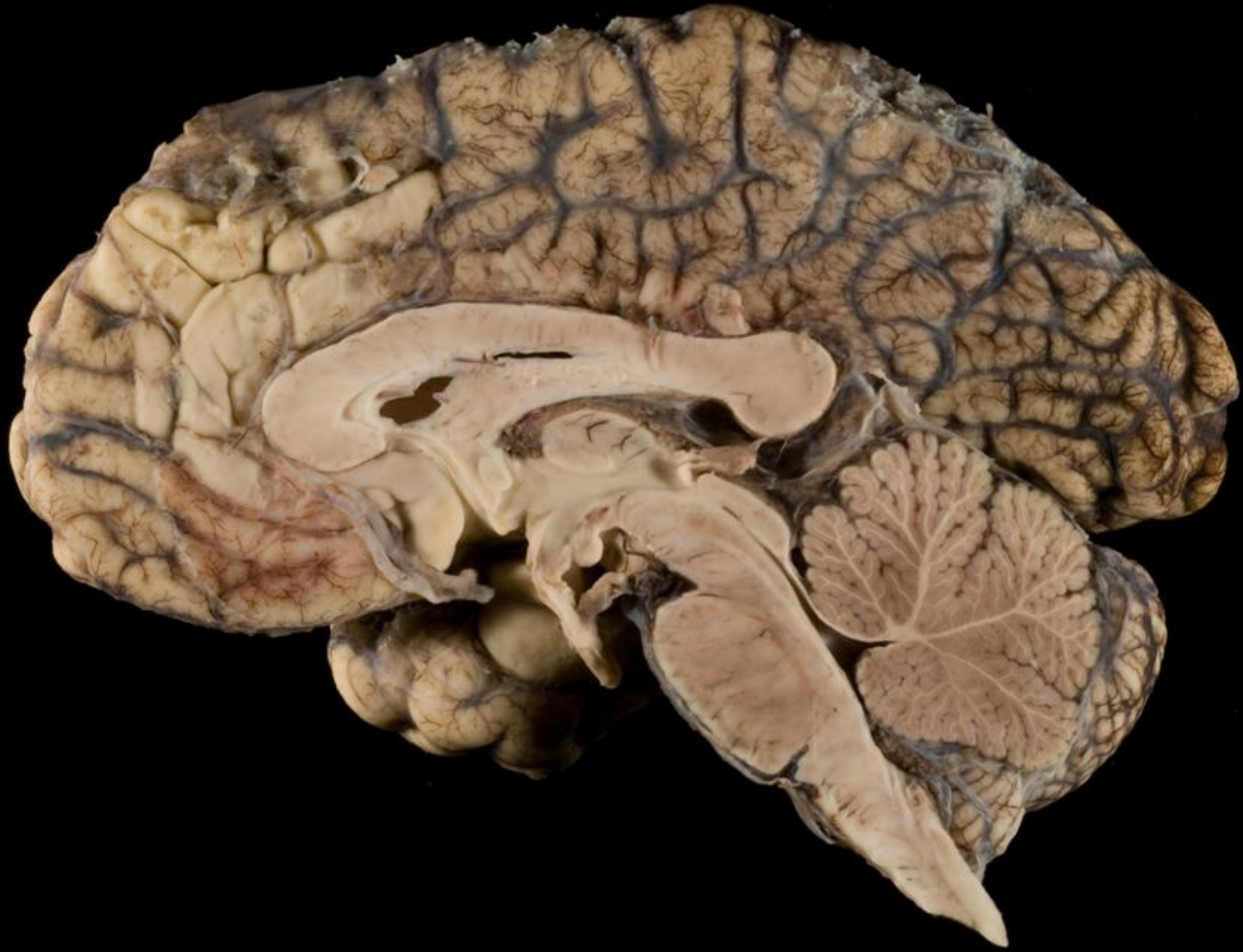A normal spinal cord with opened dura illustrates the denticulate ligaments that attach the spinal arachnoid to the spinal dura and the spinal nerve roots. The anterior spinal artery may be seen as it tranverses the anterior spinal cord.

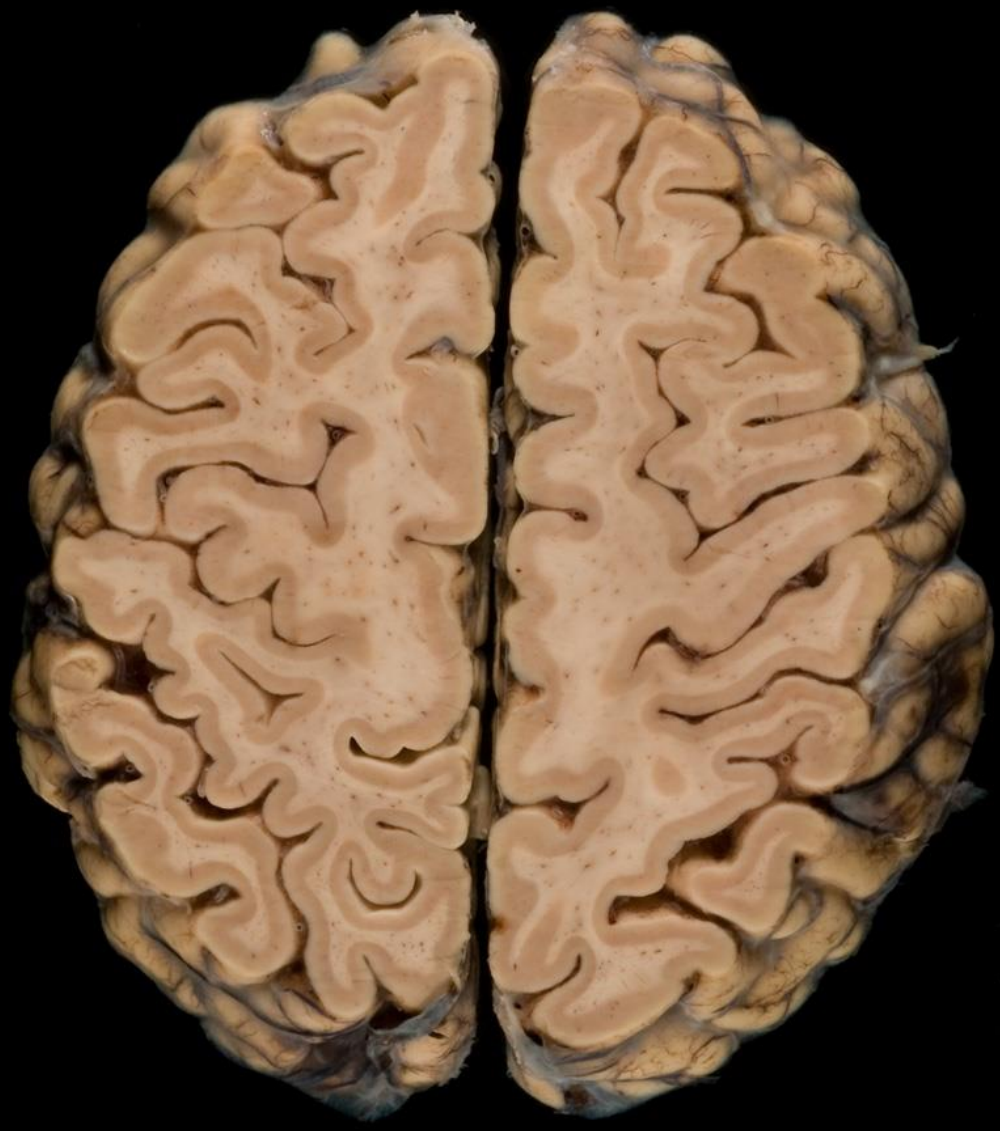


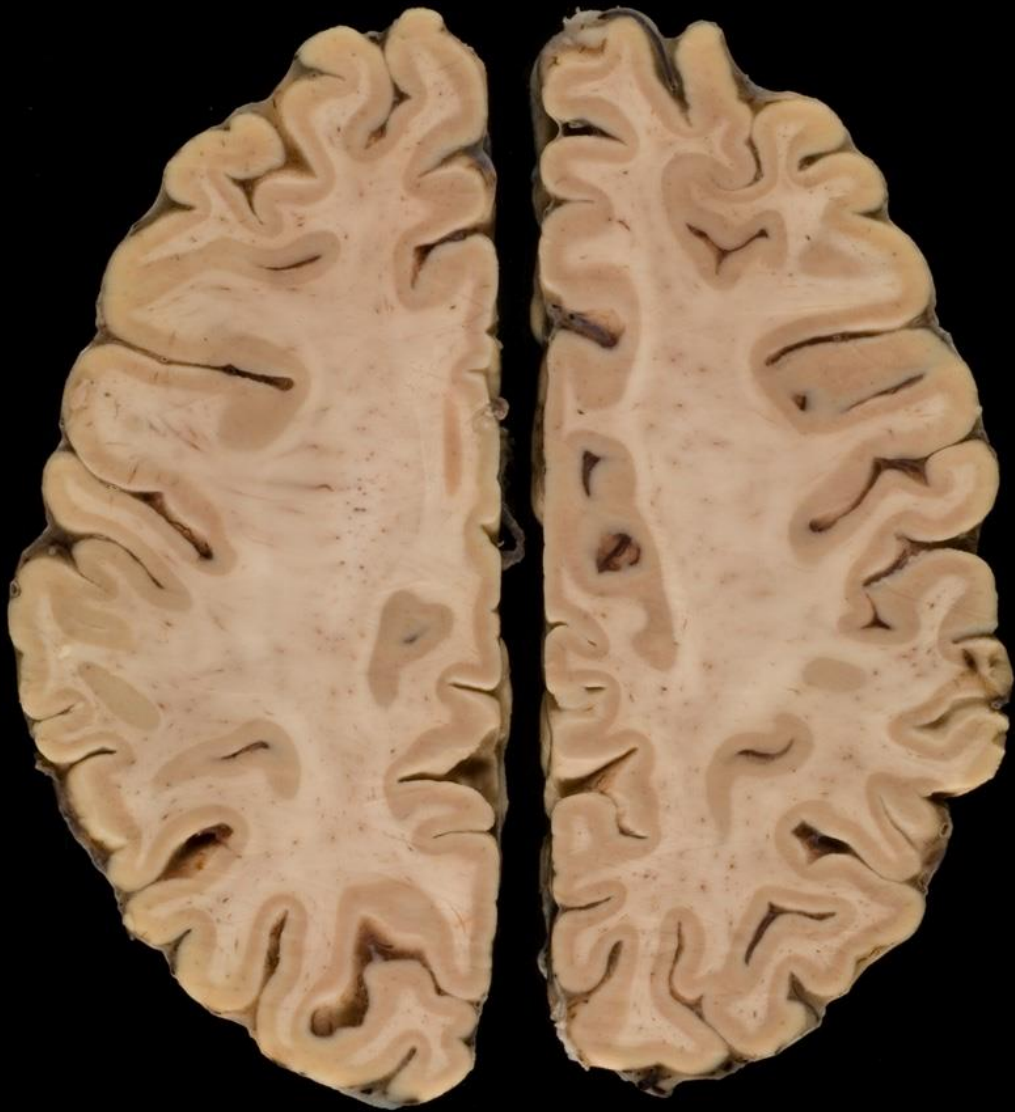




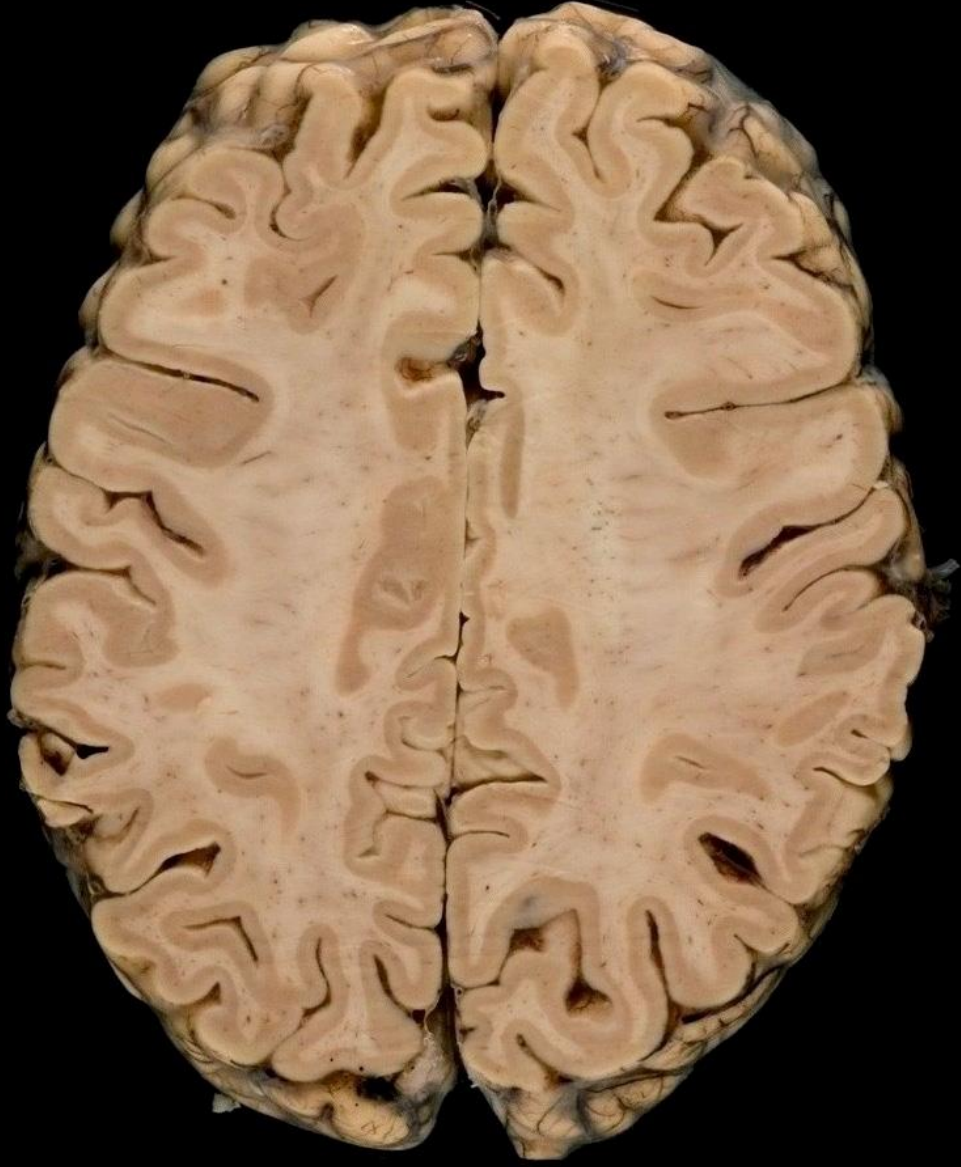

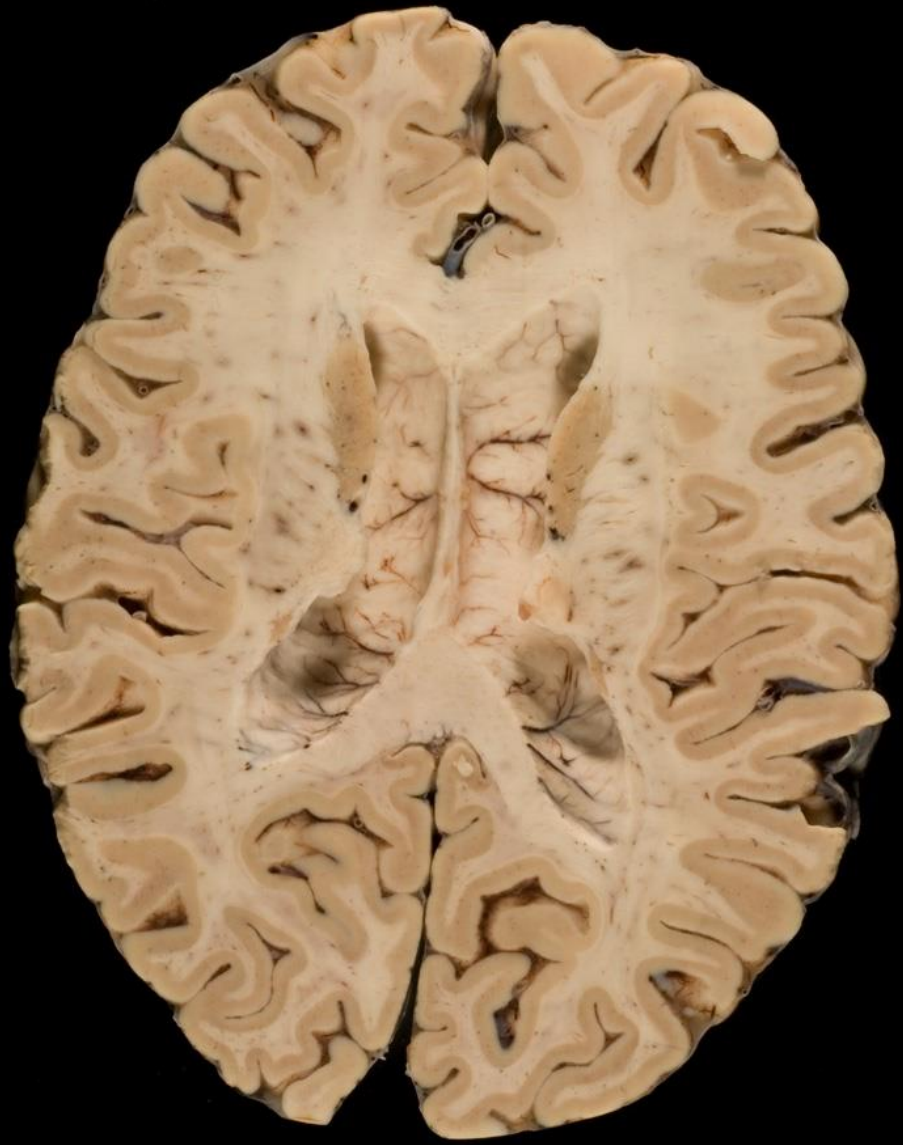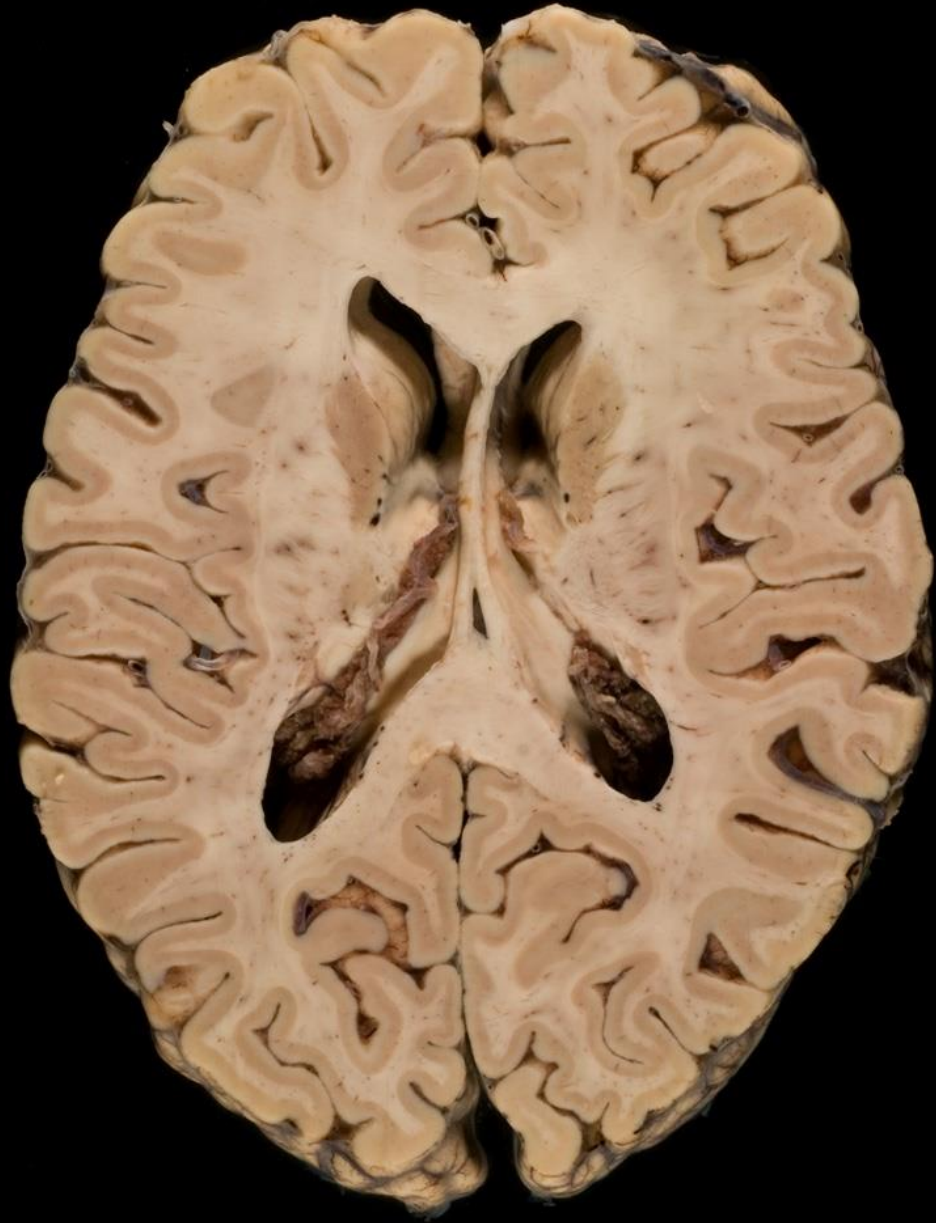






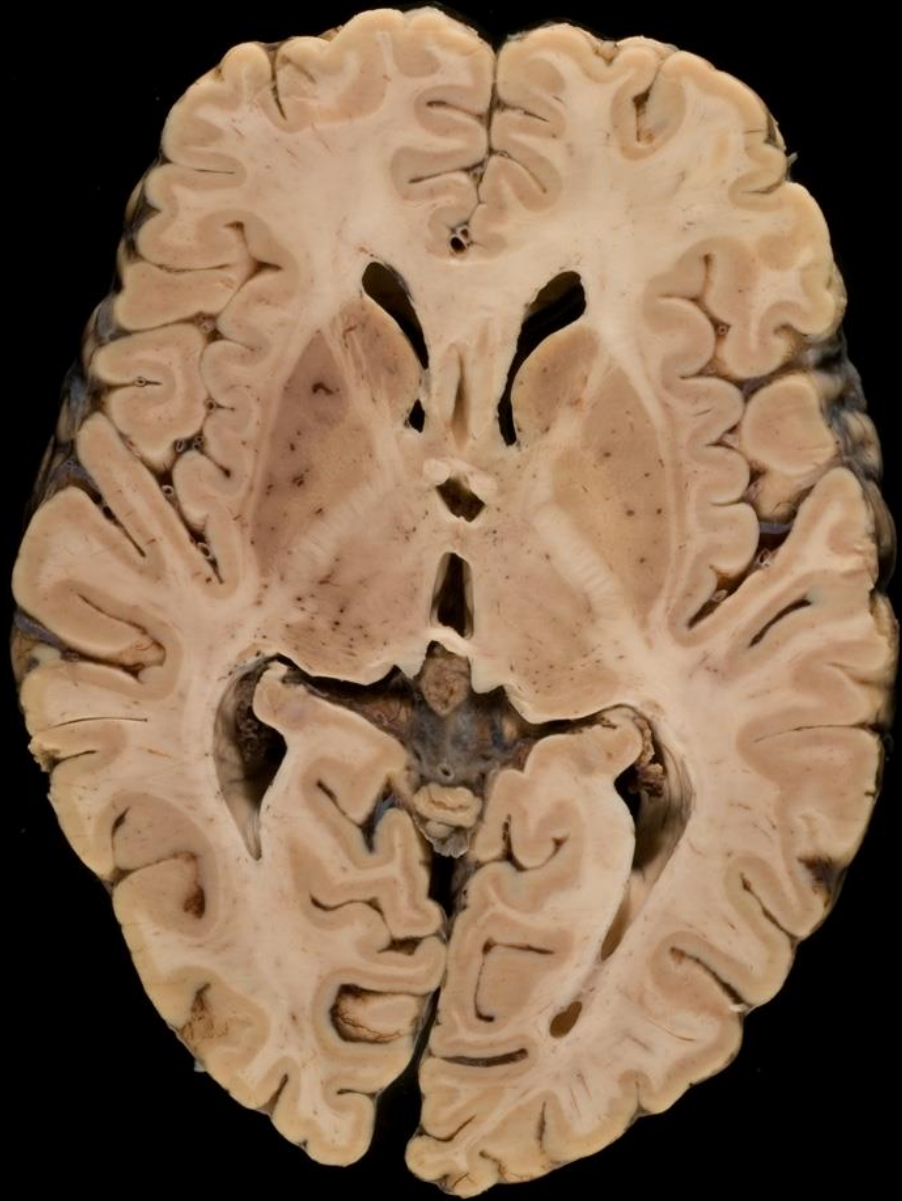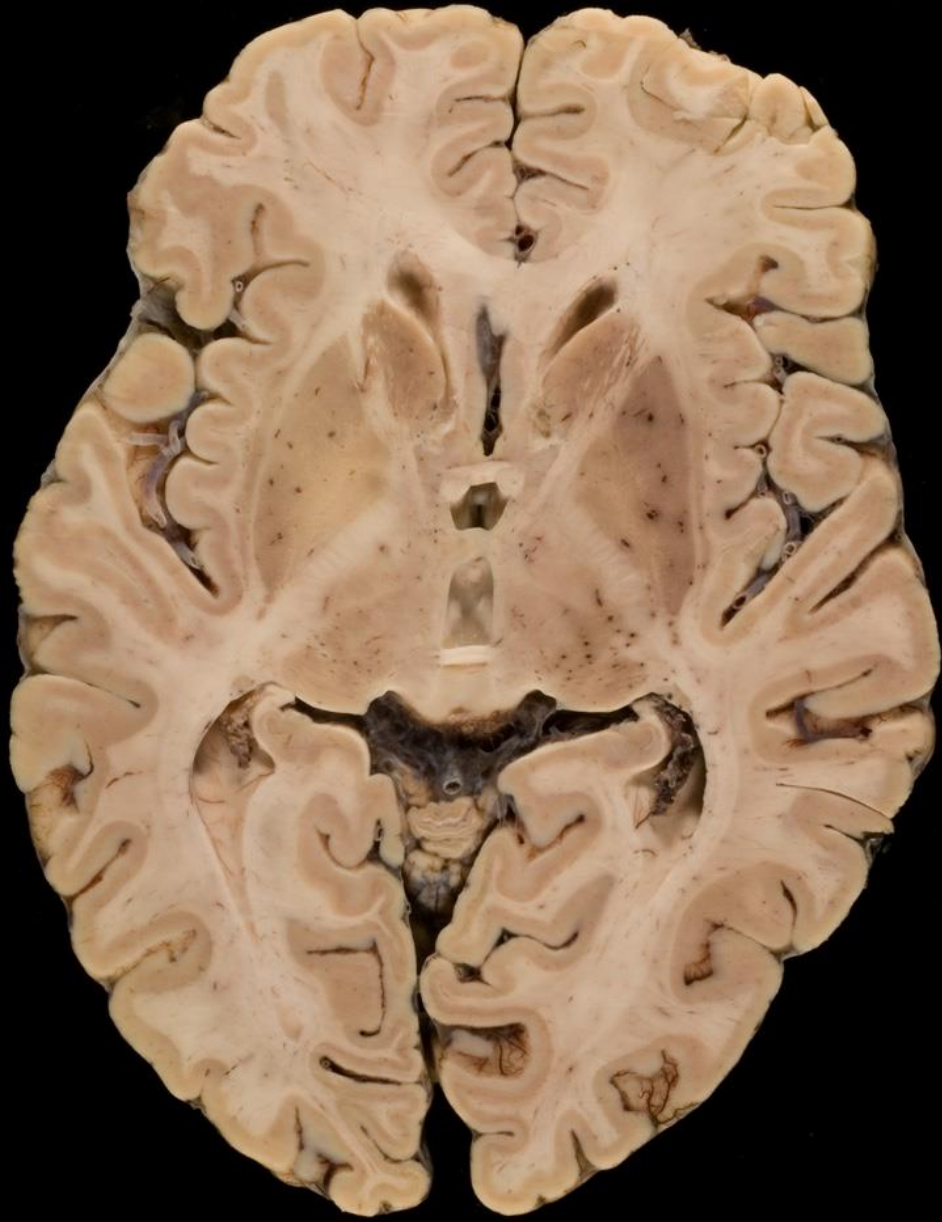









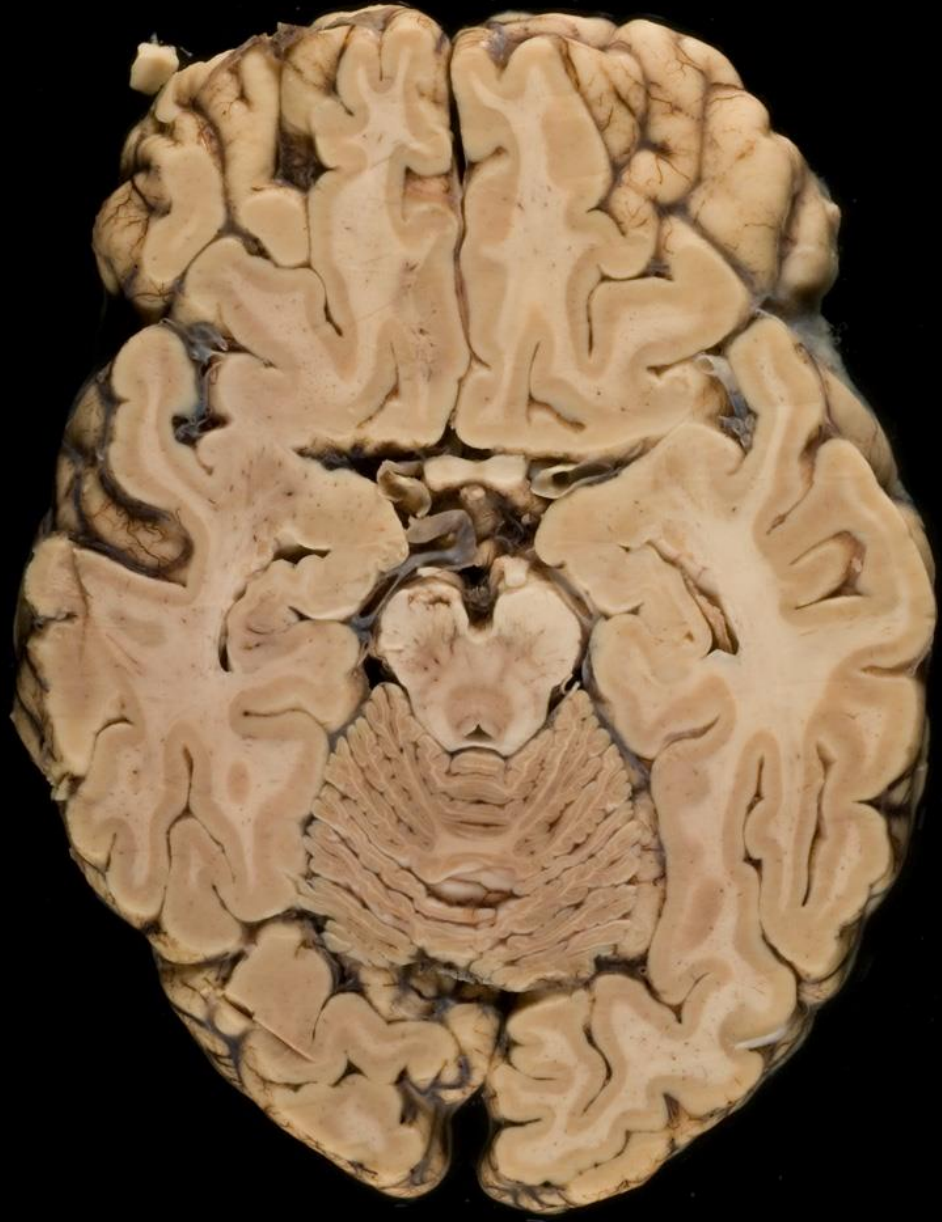








## Case 2

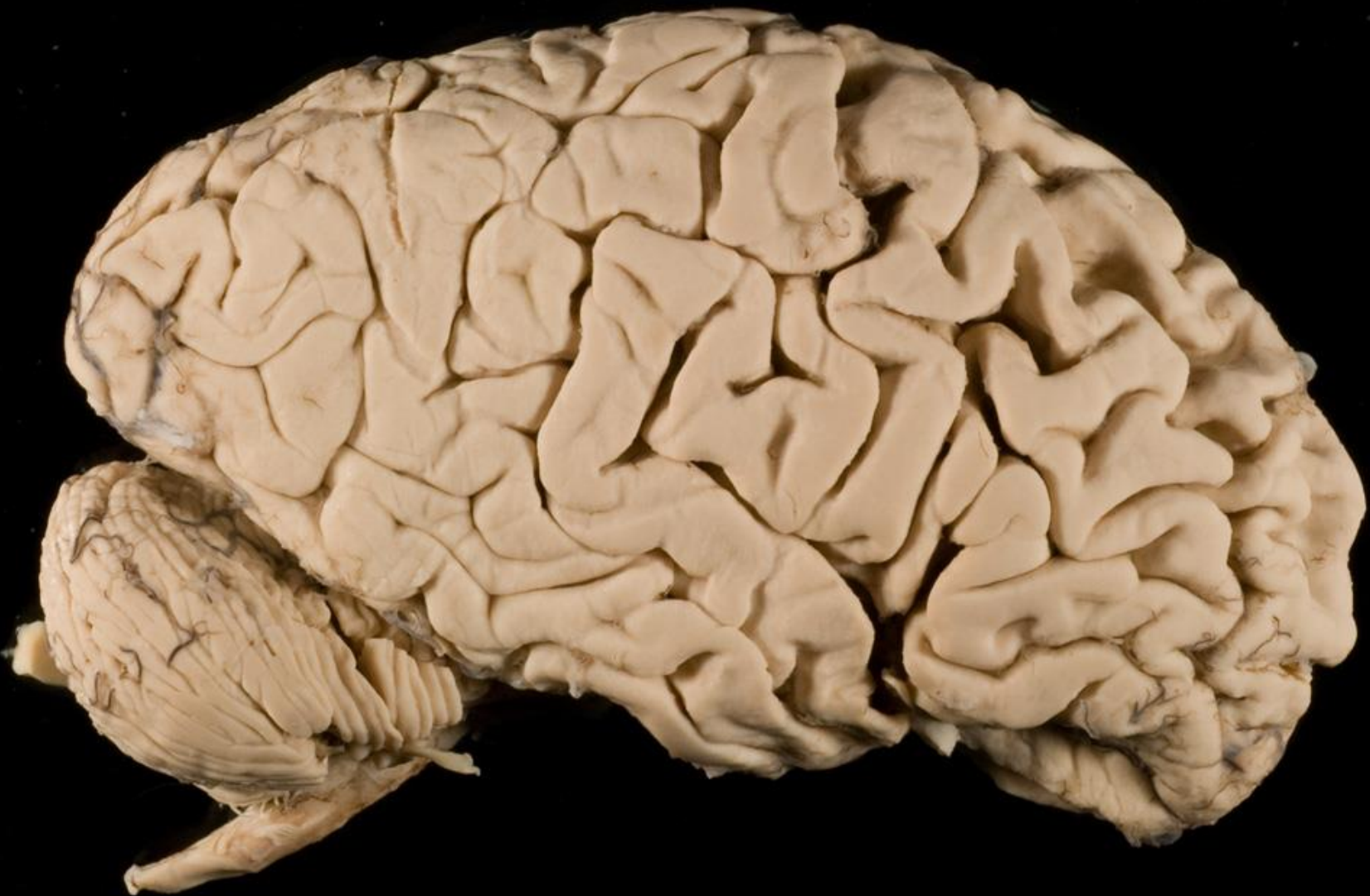Two brains; one cut in a sagittal plane, one cut in a coronal plane. The history for both cases is similar.

Clinical History: 85-year-old woman with a history of mental decline for 15 years. She first experienced forgetfulness and behavioral changes, specifically anger and suicidal ideations. Her physical health had been unremarkable except for late onset diabetes mellitus and numerous urinary tract infections. She was admitted to a health care facility 10 years prior to her death. Her decline progressed in stair-step fashion. For the last 3 to 5 years, she had been unresponsive to her family and other social interactions. During the weekend prior to her death, she began holding food and liquids in her mouth and would not swallow.

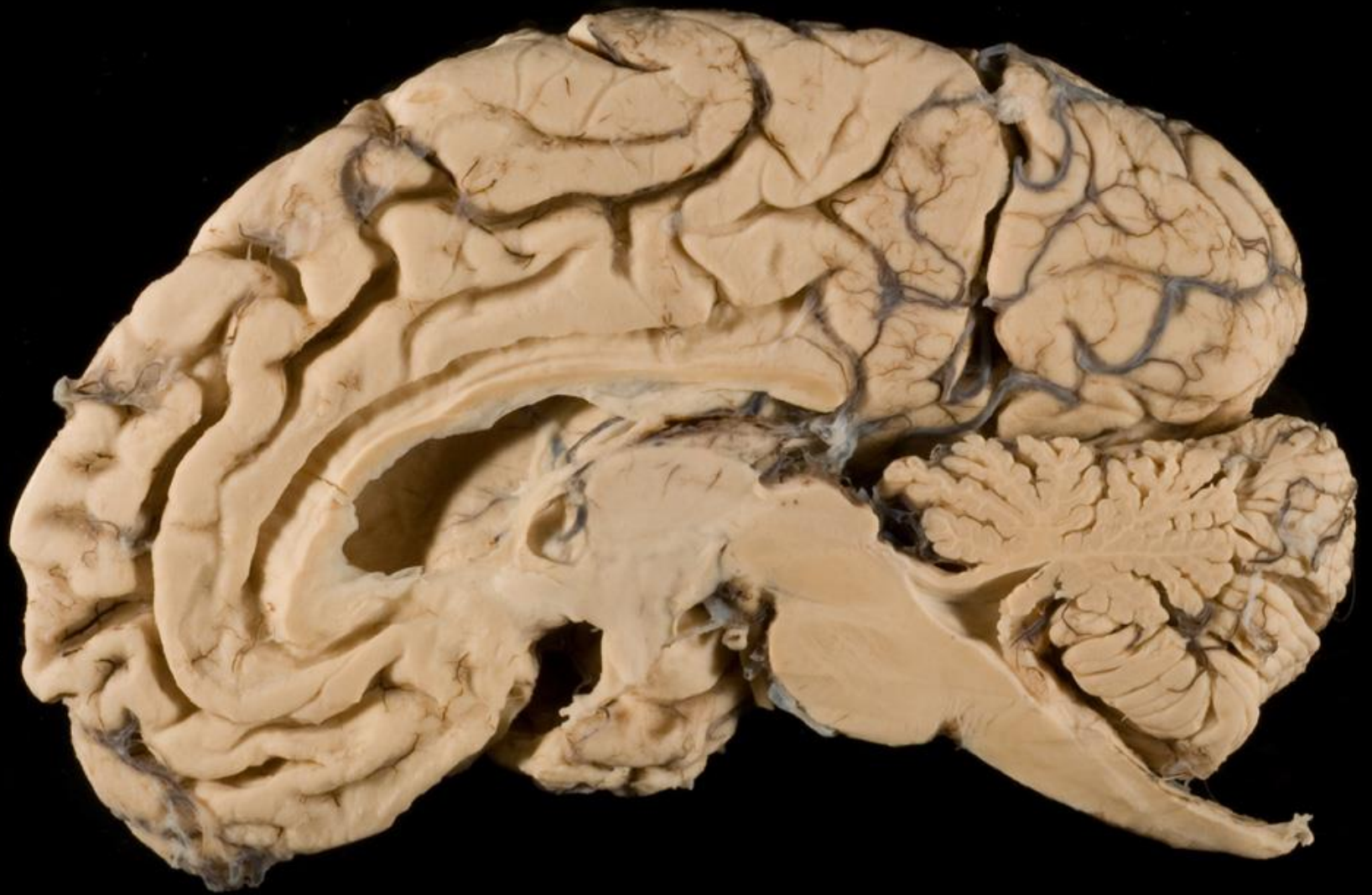Gross description: The unfixed brain weighs 1000 grams. There is mild cortical atrophy. There is moderate ventricular dilation. The hippocampus is markedly atrophic. The deep white matter, substantia nigra and caudate nucleus are normal. The absence of pathology in the deep white matter and subcortical nuclei excludes vascular dementia. The absence of pathology in the substantia nigra excludes Parkinson disease and the Lewy body disorders. The absence of pathology in the caudate nucleus excludes the frontal lobe dementias and Huntington's disease.

Microscopic description: Sections of cortex show mild to moderate neuronal loss and gliosis. Immunostains for AT8 tau show frequent neurofibrillary tangles. Immunostain for beta amyloid show frequent plaques. There is moderate vascular amyloid. Synuclein stain for Lewy bodies is negative.

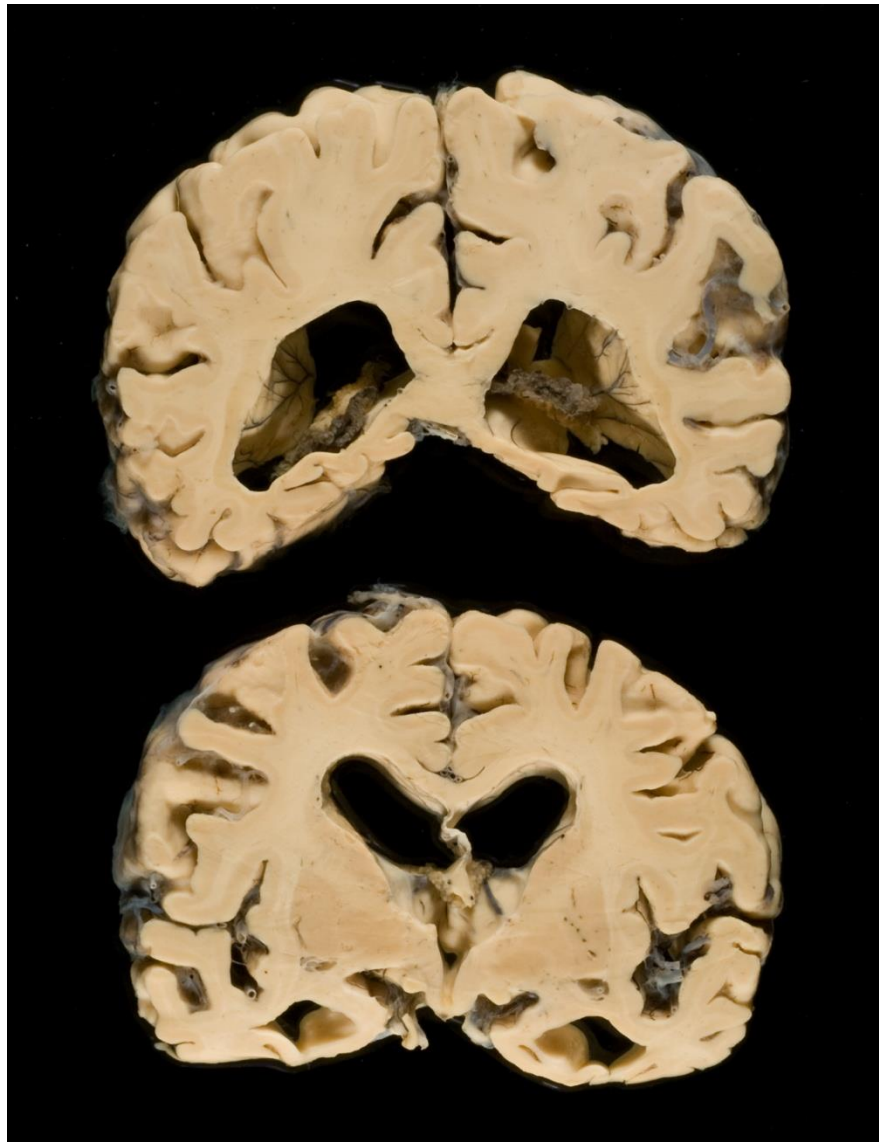**DIAGNOSIS:** Alzheimer Disease

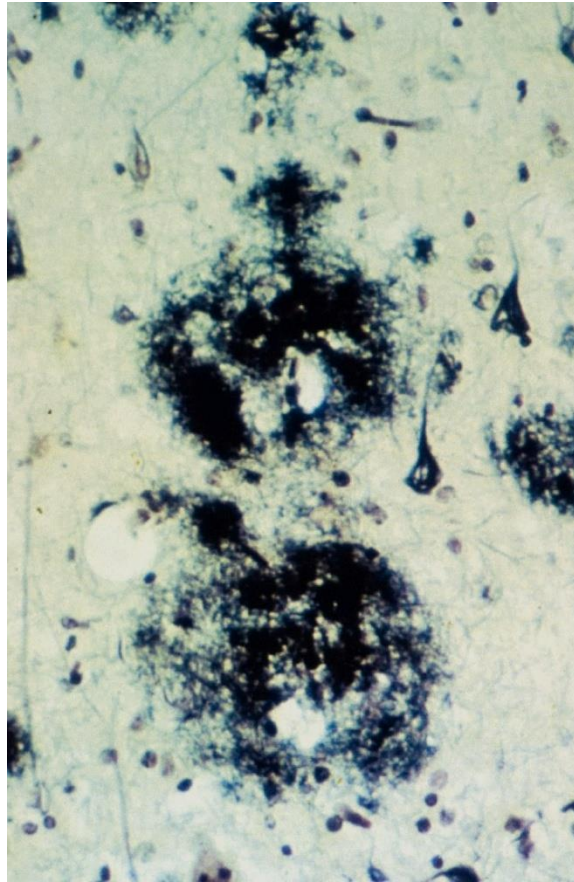




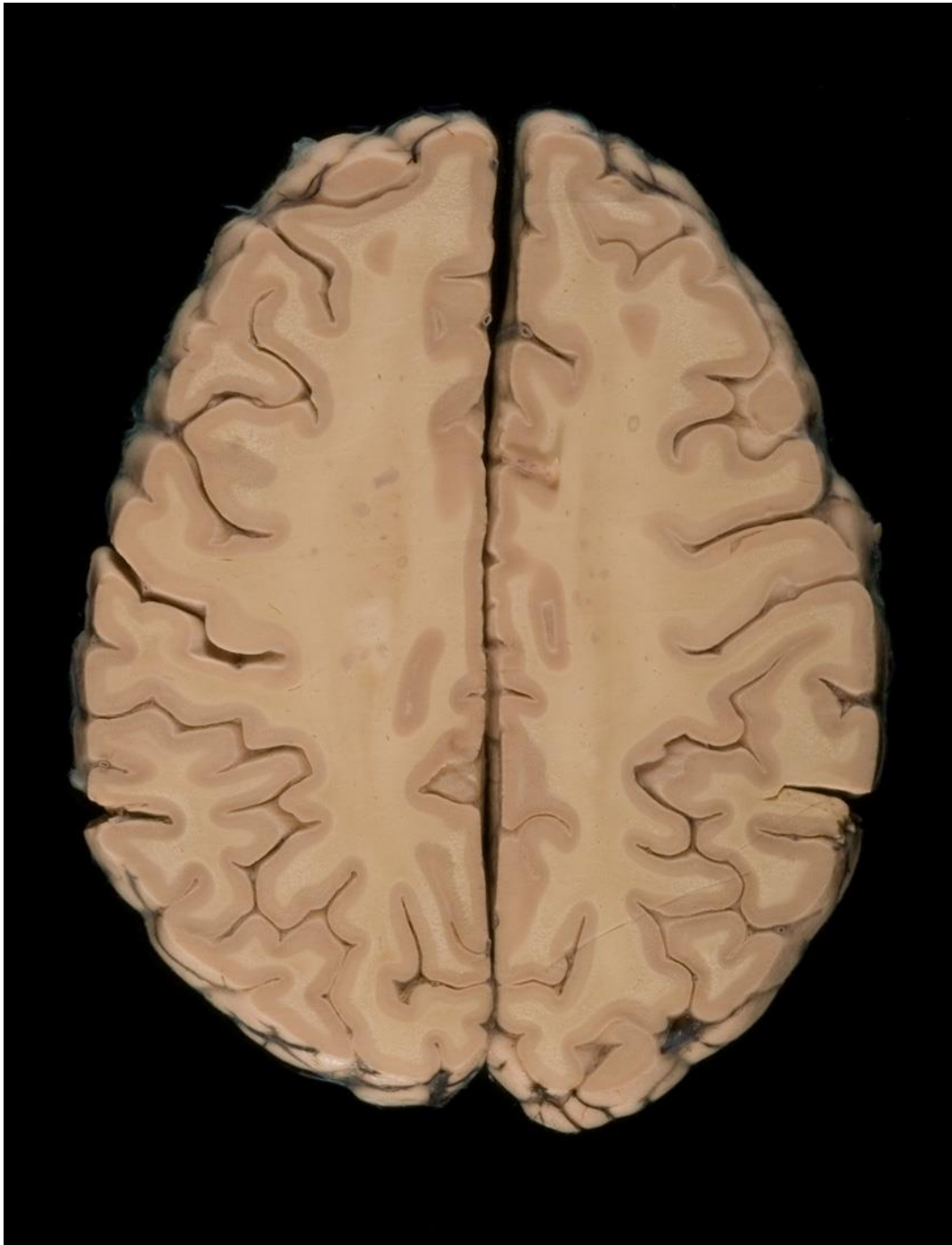


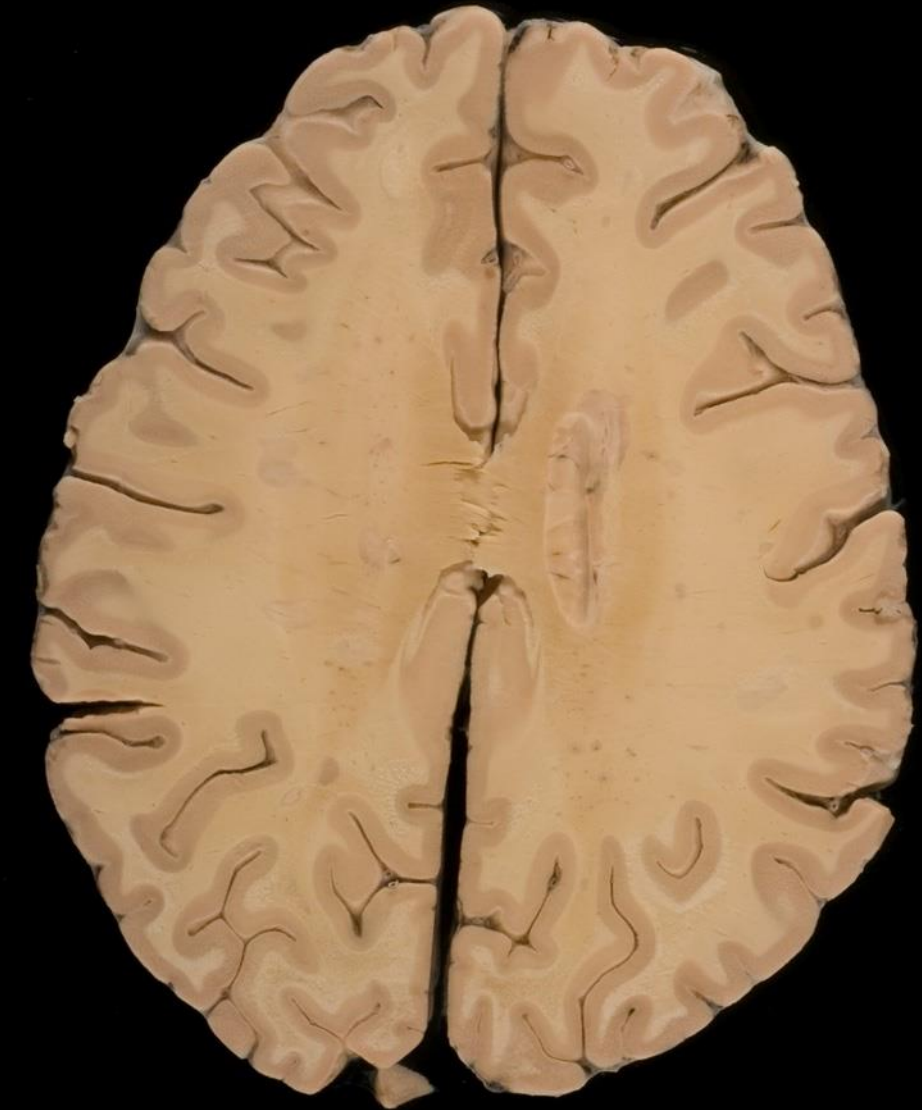



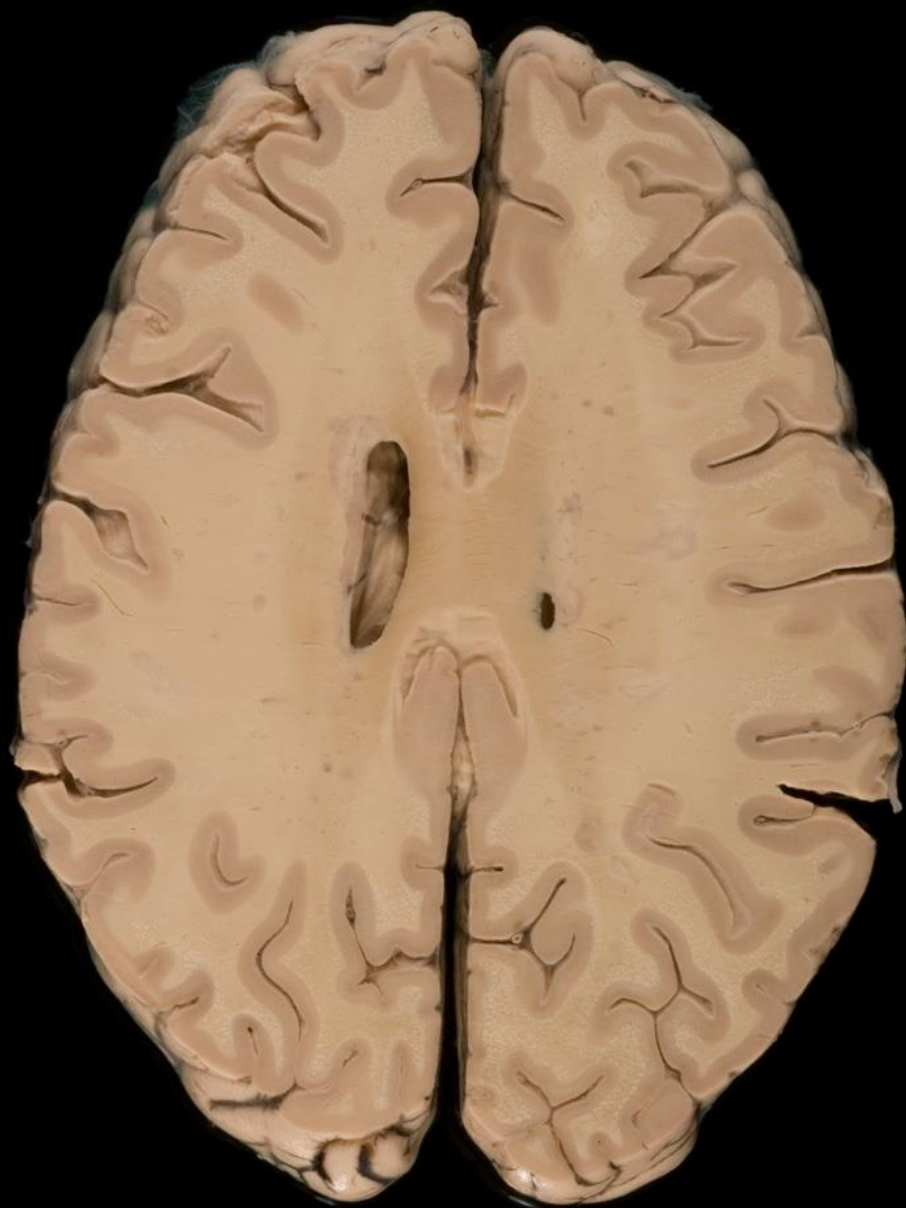


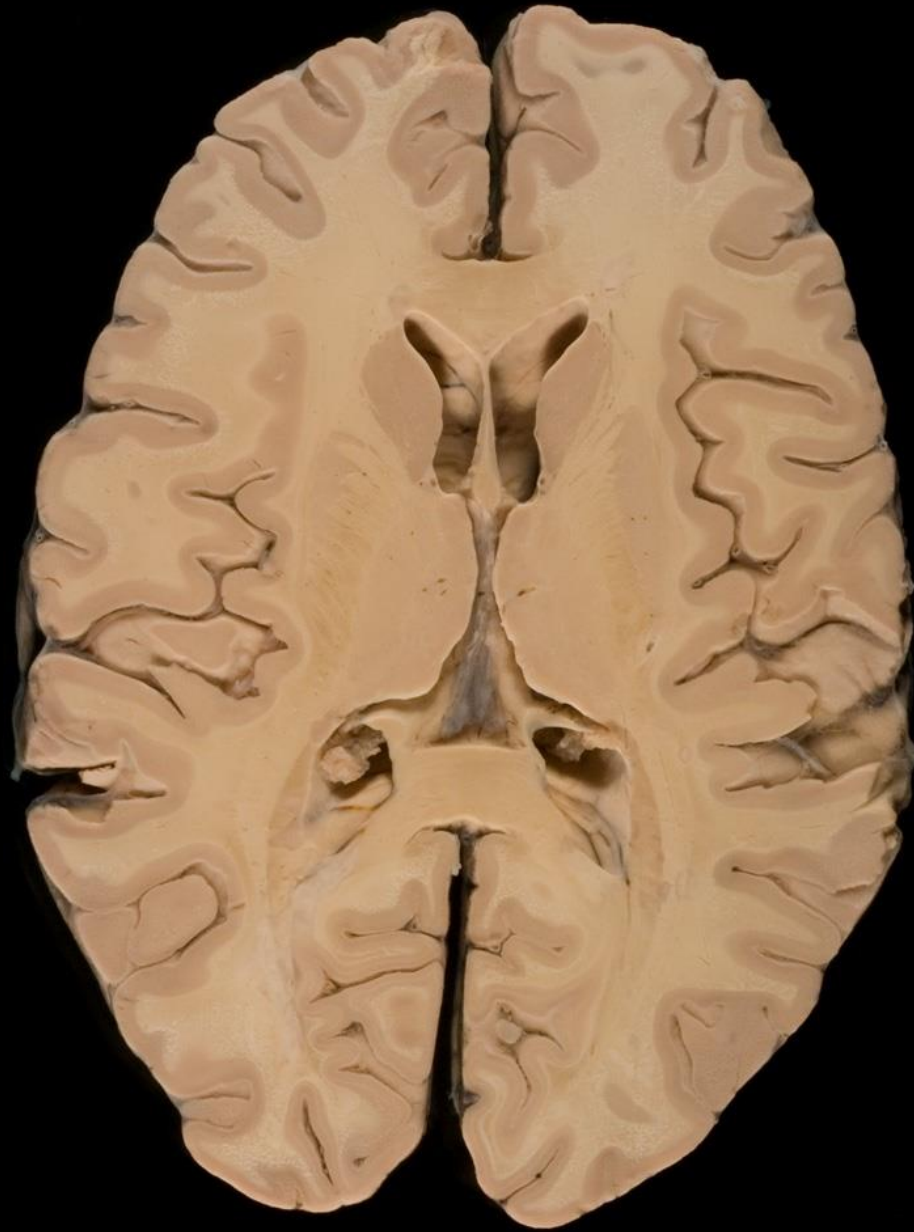- **Case 3**
- **Clinical History:** The patient was a 43 year old white female who was confined to a wheelchair due to multiple sclerosis. She was found unconscious by her family. An empty medication bottle was found at the patient's side. The patient was taken to the emergency department where it was discovered that she had no spontaneous respiration and no withdrawal to pain. Her pupils were fixed and dilated.
- **Gross description:** The unfixed brain weighed 1050 grams. The brain is sectioned in the horizontal plane and showed numerous 0.1 to 0.5 cm diameter gray brown plaques in the white matter tracts of the neocortex, brain stem and pons. Plaques were also present in the spinal cord.
- **DIAGNOSIS:** Multiple Sclerosis









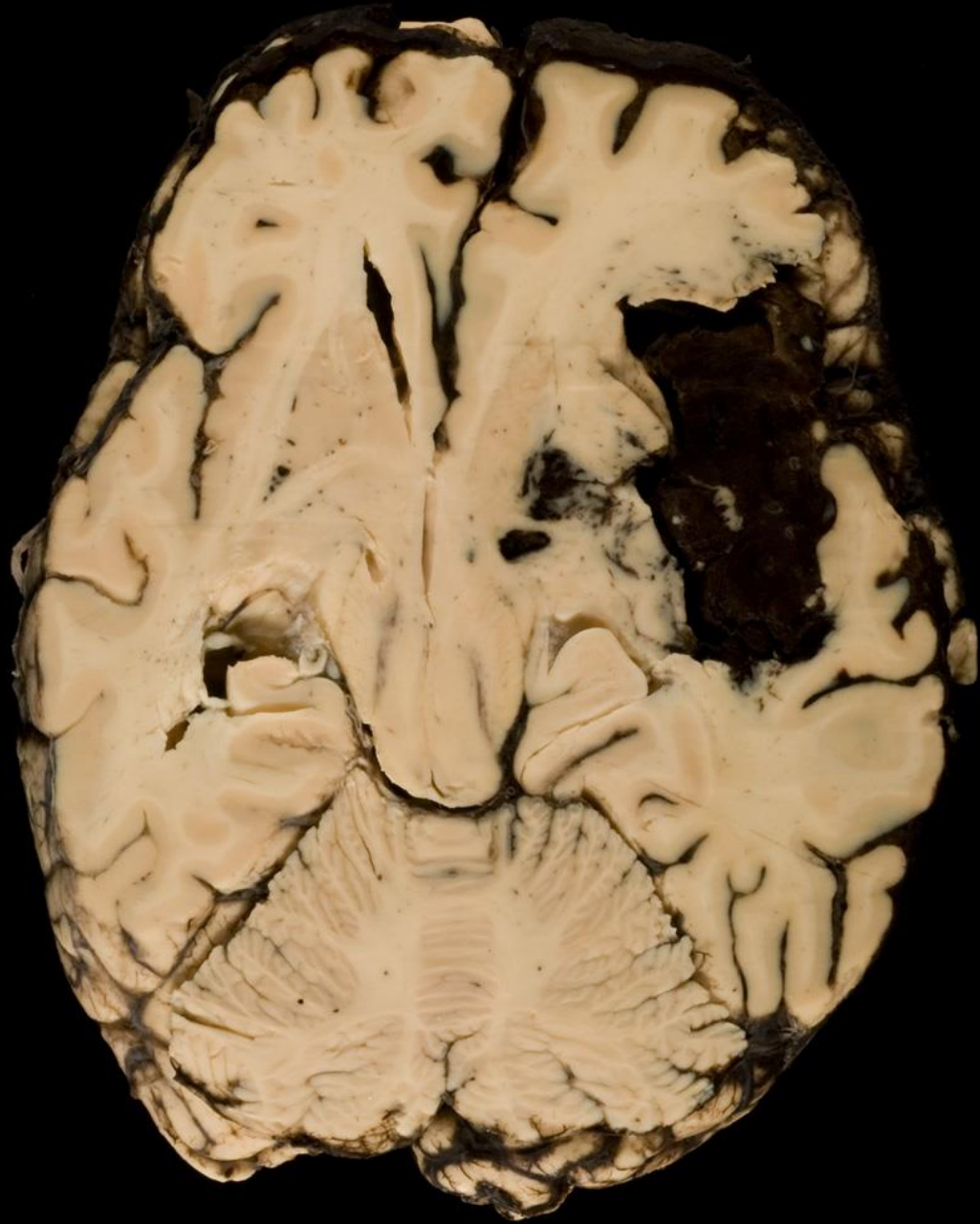


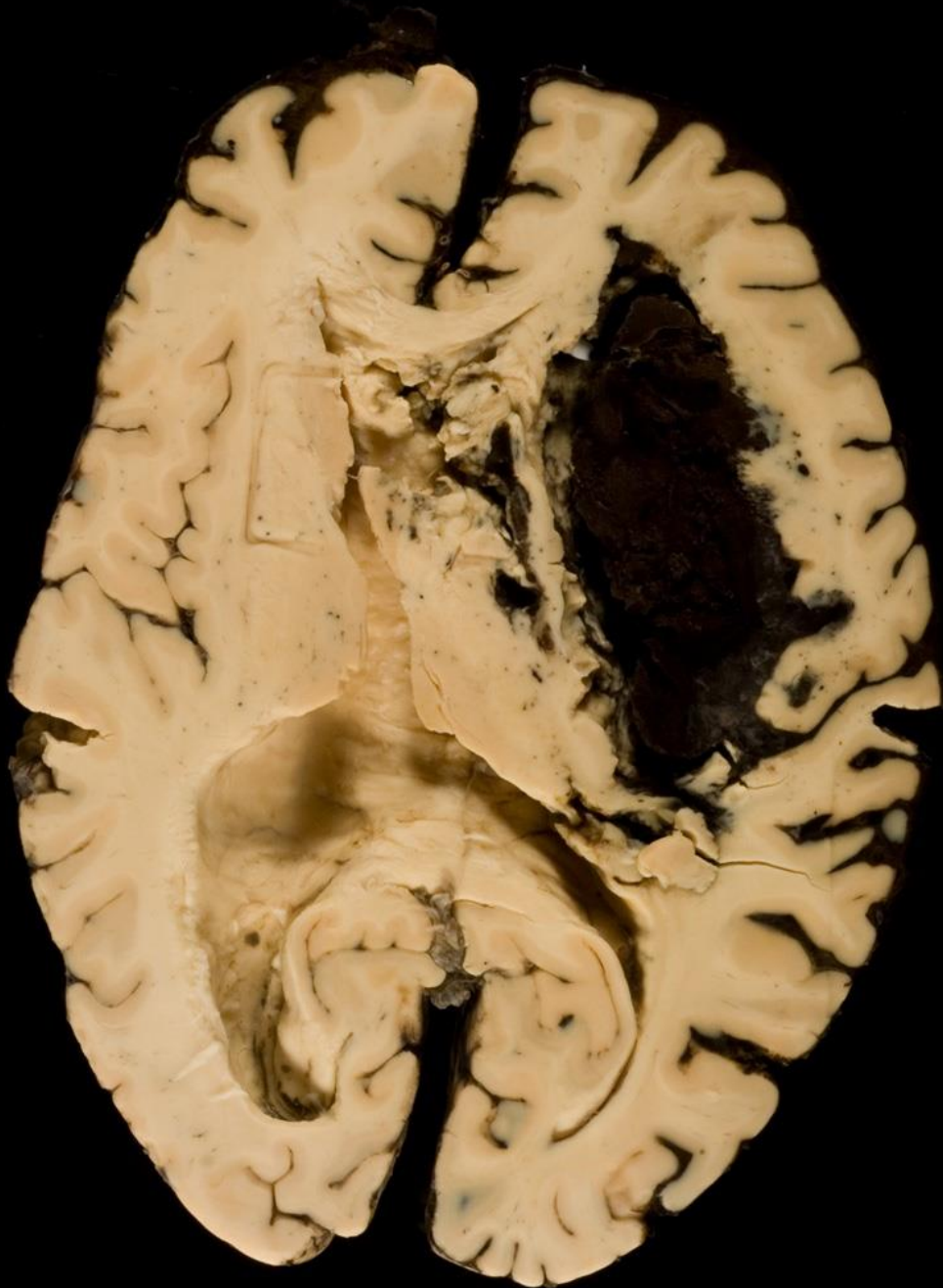## **Case 4**

**Clinical history:** 35 year male was at a party. He clutched his head and fell to the ground. EMS was called and the patient was transported to the hospital where he was unresponsive. Blood pressure upon arrival at the ED was 230/90. His companions were questioned and admitted that he had used alcohol and crack cocaine in the past.

**Gross description:** The brain has been sectioned in the horizontal plane. There is an intracerebral hemorrhage originating in the basal ganglia. There is minimal involvement of the ventricular system.

**DIAGNOSIS:** Intracerebral hemorrhage



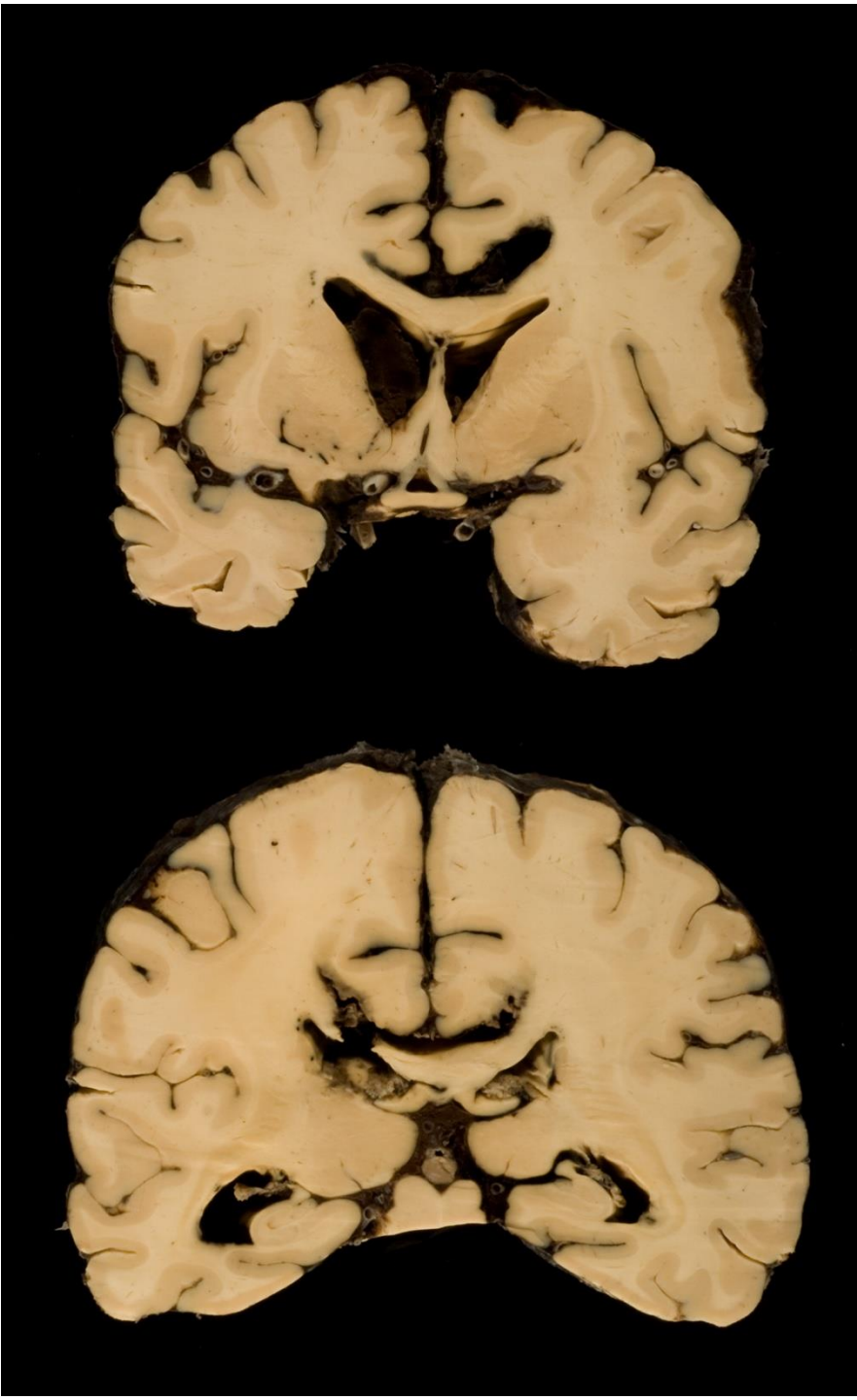




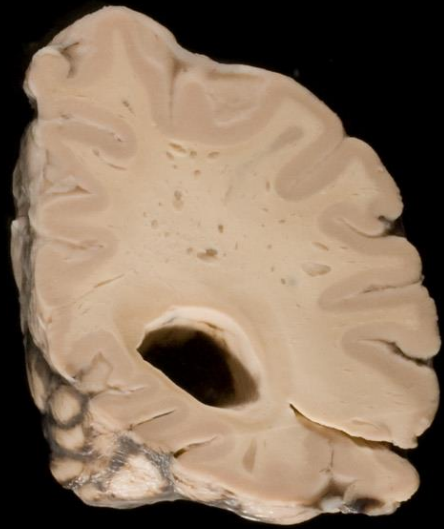
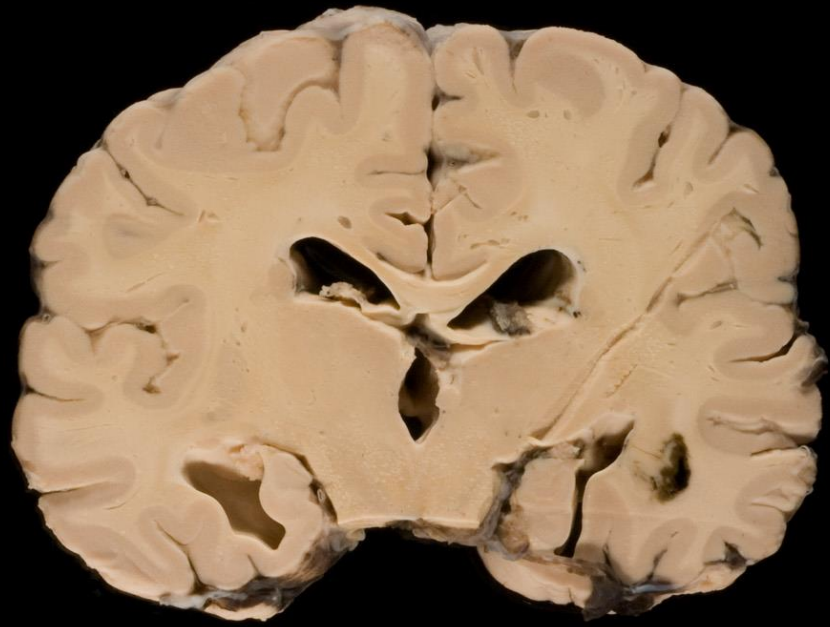- **Case 5**
- **Clinical history:** A 66-year-old male with a past medical history of hypertension was brought in an unresponsive state to Nash Hospital via EMS on January 18, 2006. A CT scan showed a massive subarachnoid hemorrhage. He was transferred to Duke and a CT angiogram revealed a left pericallosal/callosal marginal bifurcation aneurysm.
- **Gross description:** The unfixed brain weighs 1184 grams. The calvarium is remarkable for an intraventricular shunt, which enters the right midparietal lobe. The dura is remarkable for diffuse epidural blood consistent with recent surgery. The subdural surface is unremarkable. The brain is remarkable for severe diffuse bilateral subarachnoid hemorrhage. The vessels at the base of the brain reveal no gross evidence of atherosclerosis. There is diffuse swelling of the brainstem with herniation of the cerebellar tonsils, brainstem, and uncus bilaterally. The brain is sectioned coronally. It is remarkable for an intracerebral hemorrhage which appears to originate from a right-sided pericallosal aneurysm at the level of the head of the caudate nucleus. Associated with this aneurysm there is intraparenchymal hemorrhage extending from the level of the genu of the corpus callosum caudally to the mid corpus callosum at the level of the thalamus. The intraparenchymal hemorrhage measures approximately 4 x 3 x 3 cm. There is disruption of the left corpus callosum at the level of the pulvinar with an associated intraventricular hemorrhage. There is diffuse intraventricular hemorrhage involving the lateral ventricles bilaterally, the temporal horn of the lateral ventricle, third ventricle, and the fourth ventricle. There is a hemorrhagic infarct of the left thalamus, which measures approximately 1 cm in diameter. There is diffuse dissection of the hemorrhage into the cerebral parenchyma at the level of the splenium of the corpus callosum.

- **DIAGNOSES:**

- 
- 
- Right pericallosal atherosclerotic aneurysm with rupture and right frontal intracerebral hemorrhage, 4 x 4 x 3 cm, left-sided disruption of the corpus callosum and intraventricular hemorrhage.
- Cerebral edema with herniation of the brainstem, cerebellar tonsils and uncus bilaterally.

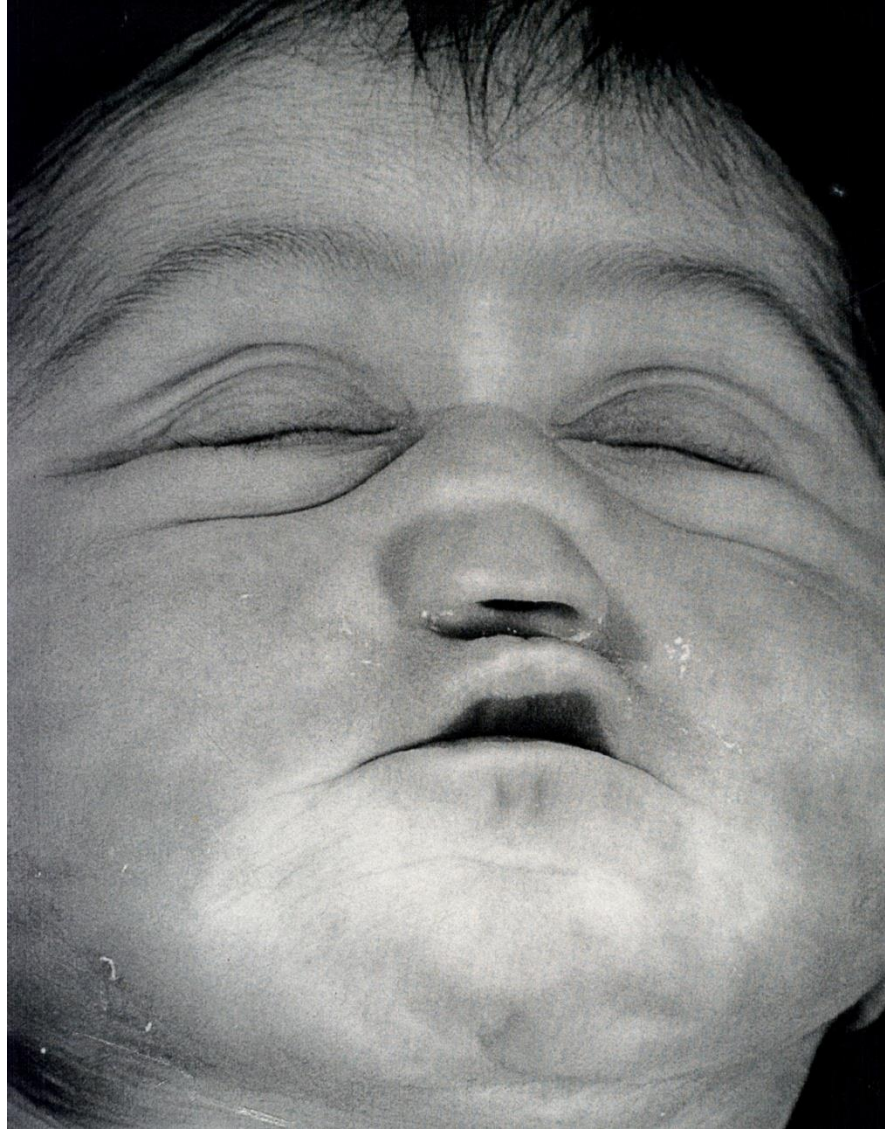

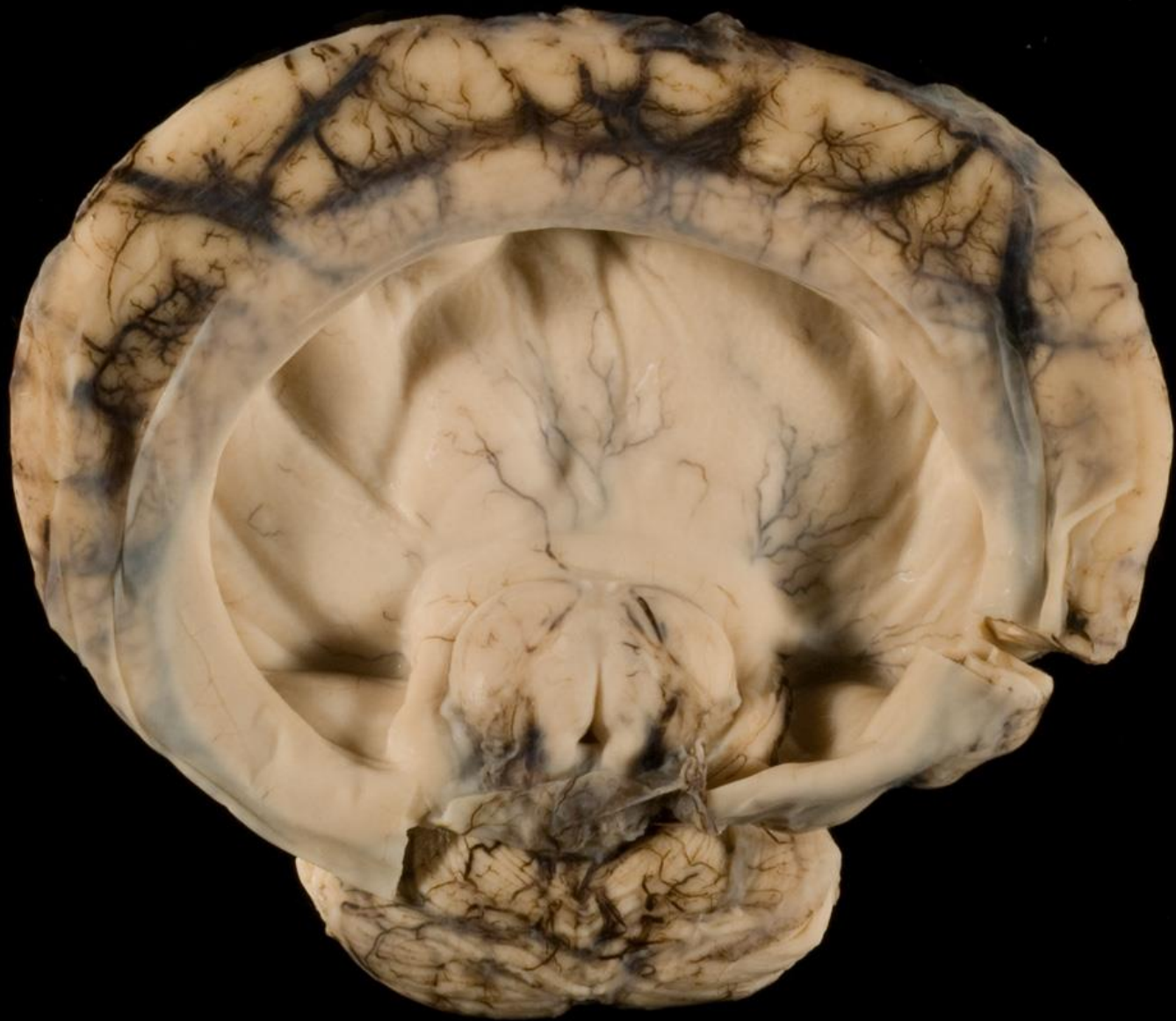- **Case 6**
- **Clinical History:** At 21 months of age the patient was referred to a Pediatric neurologist for bilateral strabismus. CT of the brain revealed posterior, sagittal and lambdoidal synostosis, bilateral proptosis and multiple low intensity lesions in the white matter of the corpus callosum. These findings were consistent with mucopolysaccharidosis. Testing revealed low alpha-L-iduronidase activity indicative of Hurler type mucopolysaccharidosis. The patient was referred to the Pediatric bone marrow transplantation unit. He underwent umbilical cord blood transplantation from an unrelated donor with a single mismatch of the HLA complex. Subsequently the patient developed graft vs. host disease and cytomegalovirus infection. The patient expired three months after bone marrow transplantation.
- **Gross Description:** There is a moderate ventricular dilation. There are multiple pits ranging from 1 x 3mm in diameter in the white matter. These lesions are most numerous and in the parietal occipital lobes but they are also present in the frontal cortex. There is also large acute intracerebral hemorrhage of the right inferior temporal lobe.
- Glycosaminoglycans (GAGs) accumulate in blood vessels and meninges. Accumulation of GAG's causes dilation of the perivascular spaces with very loose connective tissue forming pits. Neuronal storage product is evident on microscopic examination.
- **DIAGNOSIS: Hurler's Syndrome (Mucopolysaccharidosis I-H).**



- **Case 7**
- **Clinical History:** This infant was delivered at 41 weeks gestation. At delivery hypotelorism and absent nasal septum with a single nostril cleft palate syndrome was noted. CT of the brain revealed alobar holoprosencephaly.
- **Gross description:** The unfixed brain weighed 178 grams. On the anterior view there is no evidence of medial longitudinal fissure. The olfactory bulb and tract are absent. The optic chiasm is present but atrophic. The brain contains a single ventricular cavity with fused thalami and basal ganglia in the floor of single ventricle. The hippocampus forms a continuous arch across the ventricle. The corpus callosum is absent.
- **DIAGNOSIS:** Alobar holoprosencephaly







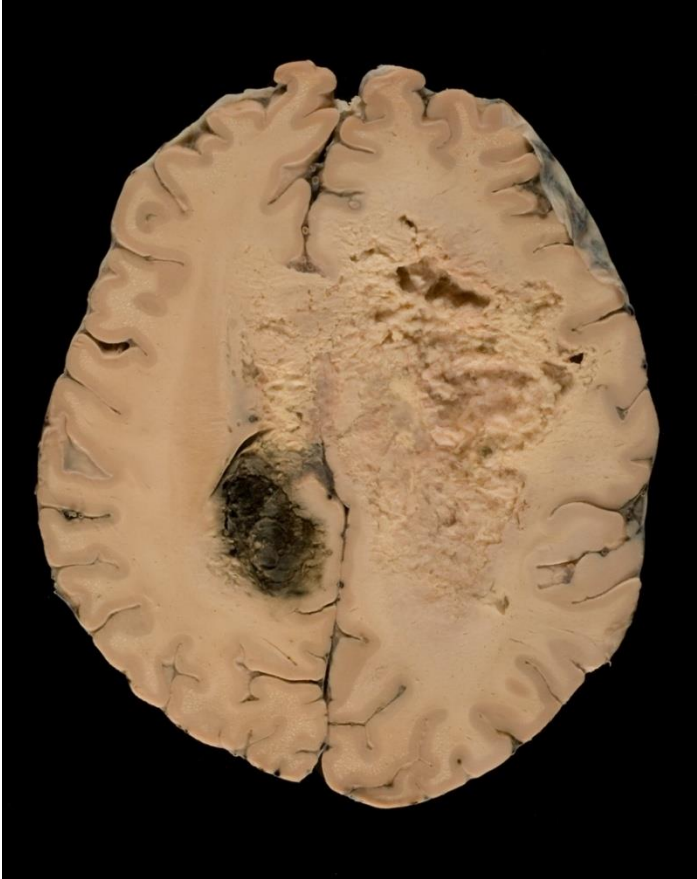- **Case 8**

- **Clinical History:** 48-year-old female had a six month history of headaches which were initially relieved with over the counter analgesics. The headaches became progressively worse and she sought medical attention. MRI was performed which demonstrated a ring enhancing tumor in the parietal lobe. A surgical biopsy was performed with a diagnosis of malignant brain tumor. She was treated with surgery, radiation and chemotherapy. However, the tumor recurred and she expired one year after diagnosis.

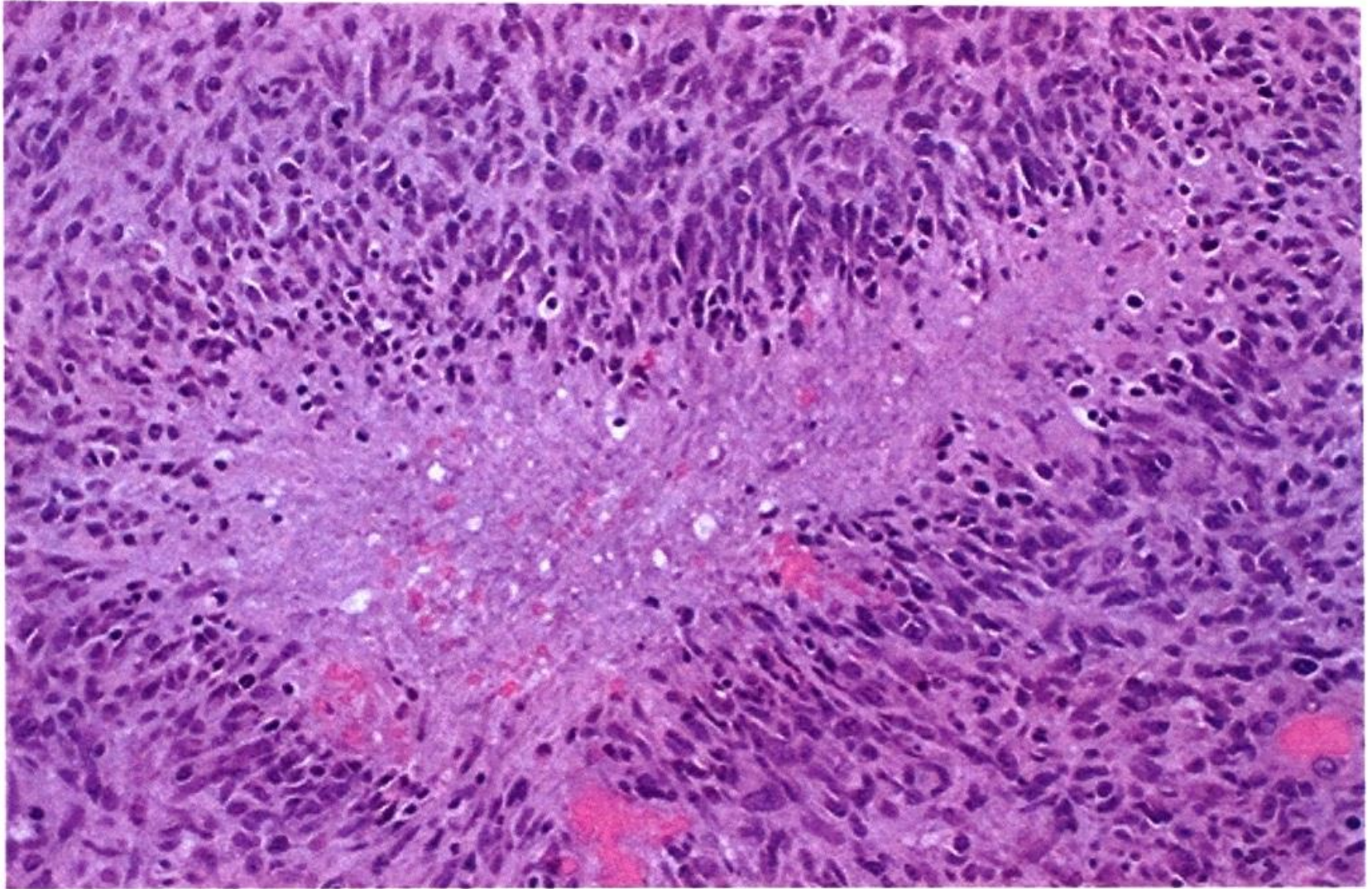
- **Gross Description:** The fixed brain weighs 1330 grams. The dura and arachnoid are unremarkable. There is no evidence of brainstem herniation. The brain is sectioned horizontally. It is remarkable for enlargement of the corpus callosum. There is a large necrotic tumor located in the parietal-occipital lobe which measures approximately 8 x 5 x 5 cm. This tumor involves the splenium of the corpus callosum and crosses to the other cerebral hemisphere. There is evidence of necrosis and cystic degeneration. There is yellow discoloration of the tumor and focal hemorrhage into the tumor. Sectioning of the brainstem and cerebellum are unremarkable.

- **Microscopic description:** Section of the medulla and left cerebellum, and pituitary gland (B1) is unremarkable. Section of the left occipital lobe (B2) shows glioblastoma with large areas of necrosis. There is focal necrosis associated with hyalinized vessels suggestive of radiation injury and therapeutic effect. Adjacent to the focus of glioblastoma there is an area of better differentiated tumor with the histological appearance of an anaplastic astrocytoma. Section of the right occipital lobe tumor (B3) is similar. Section of the left hippocampus (B4) is unremarkable. Section of the right cingulate gyrus (B5) shows infiltrating malignant glioma.

- **DIAGOSIS:** Glioblastoma



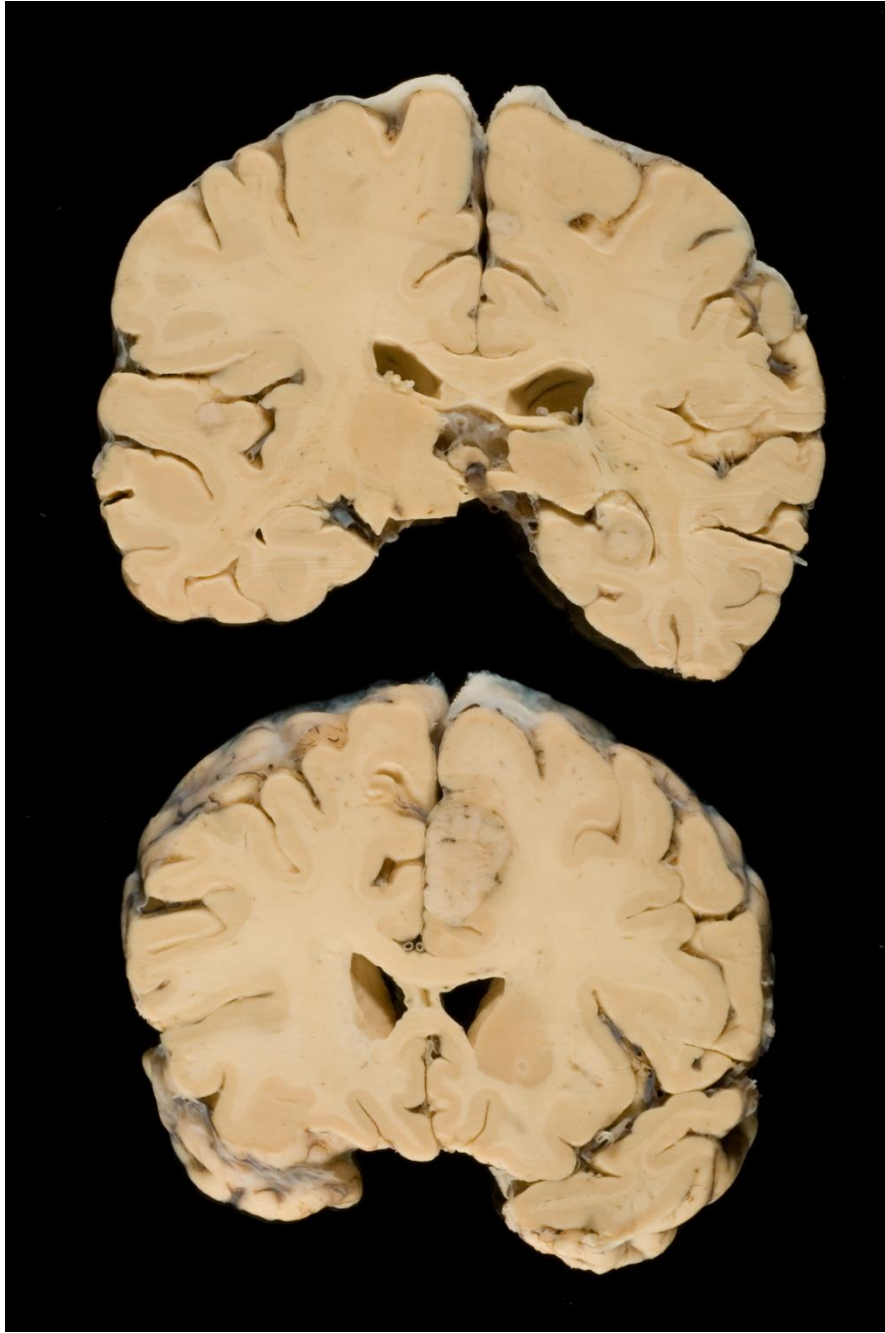


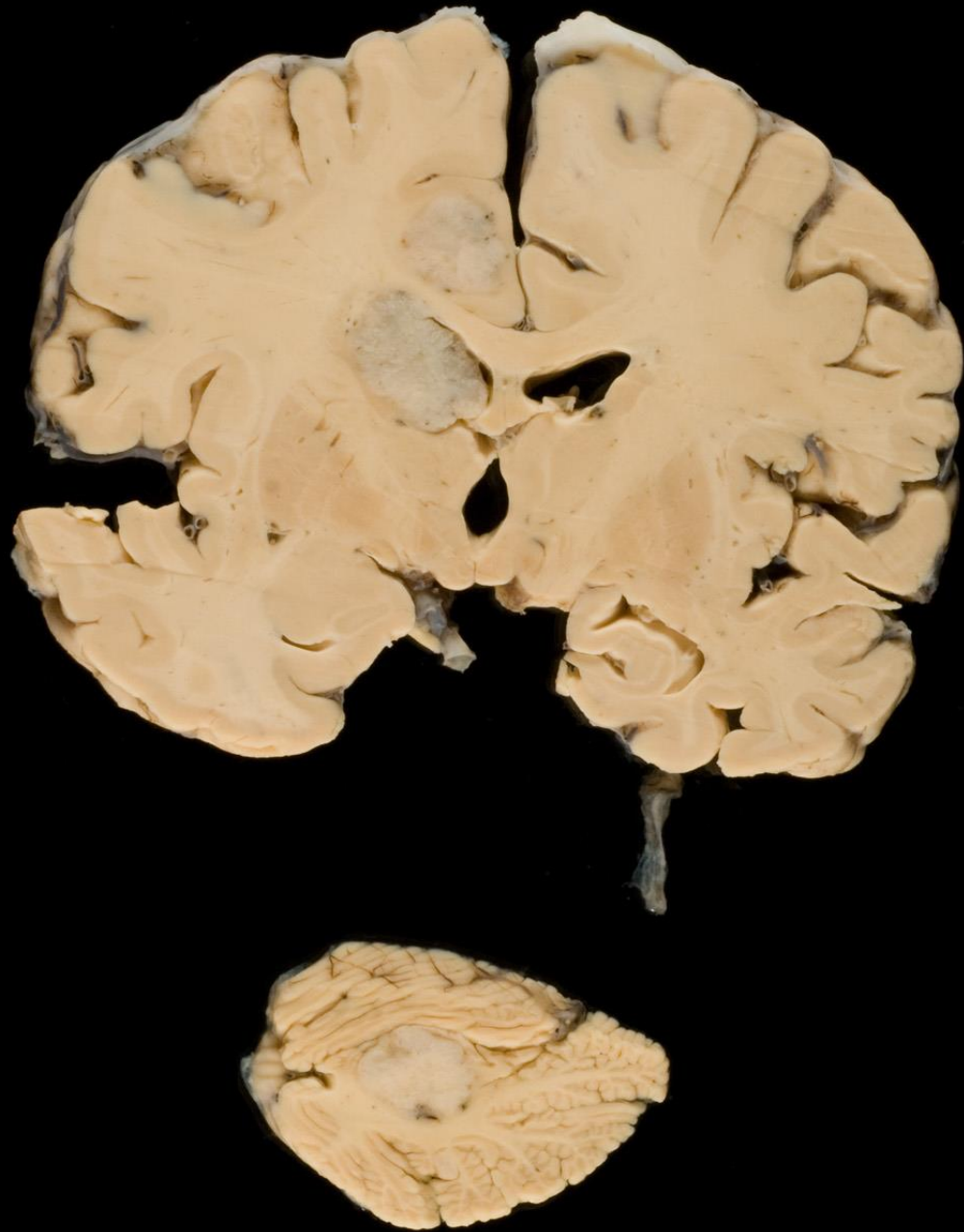
Glioblastoma



- **Case 9**
- **Clinical History:** 76-year-old lady with a non-contributory past medical history who presented to her internist in May 2007 with complaints of occasional postprandial nausea and vomiting. On physical examination, the patient was found to have right upper quadrant fullness. A CT of the abdomen revealed multiple hepatic lesions and necrotic mediastinal and porta hepatis nodes, consistent with the appearance of metastases. The patient elected to forgo further diagnostic work-up or treatment and was provided palliative care. Adenocarcinoma of the gallbladder was found at autopsy.
- **GROSS DESCRIPTION:** The unfixed brain weighs 1302 grams. The dura and arachnoid are unremarkable. The vessels at the base reveal mild atherosclerosis, with 10% stenosis of the basilar artery. The brain is coronally sectioned to reveal 22 well-circumscribed metastatic lesions, predominantly at the gray-white junction of all three hemispheres and focally adjacent to the right lateral ventricle, and three in the left cerebellar hemisphere. These lesions are characterized by a white-yellow color and a soft, friable consistency, and display minimal mass effect.
- 
- **MICROSCOPIC DESCRIPTION:** Section shows metastatic well-differentiated adenocarcinoma with extensive tumor necrosis.
- 
- **DIAGNOSIS:** Metastatic adenocarcinoma involving all lobes of the bilateral cerebral hemisphere and the left cerebellum.





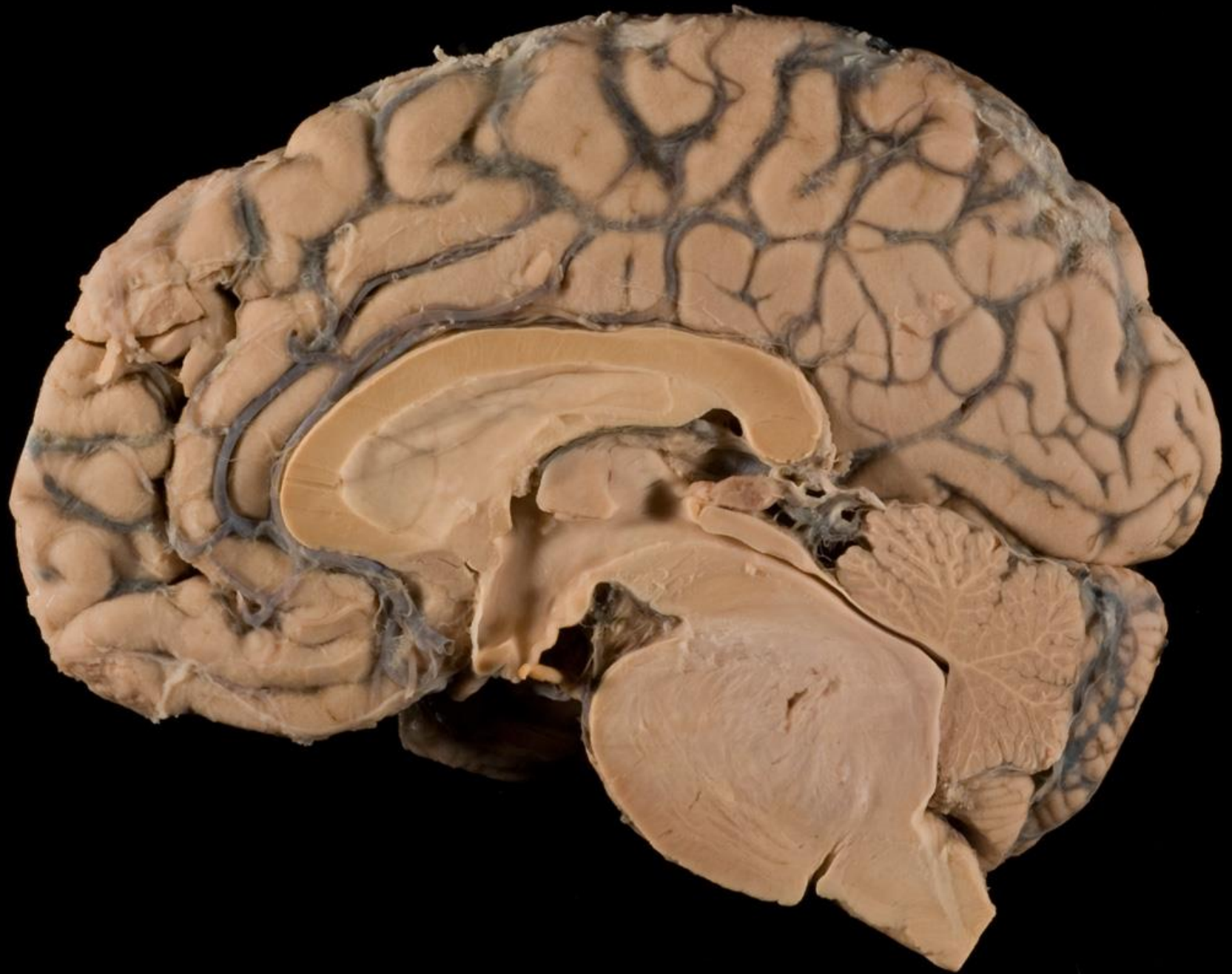- **Case 10**

- **Clinical history:** 7-year-old Caucasian male with a history of a glioma of the brainstem. At that time, he underwent a suboccipital craniotomy and C1-C2 laminectomy and laminoplasty for debulking of the tumor. Additionally, he received chemotherapy and radiation therapy, as well as a ventriculoperitoneal shunt for obstructive hydrocephalus. He had been on corticosteroids for some time prior to death and had developed a markedly cushingoid body habitus and facies. On the date of death, he was found by his family unresponsive in his bed.

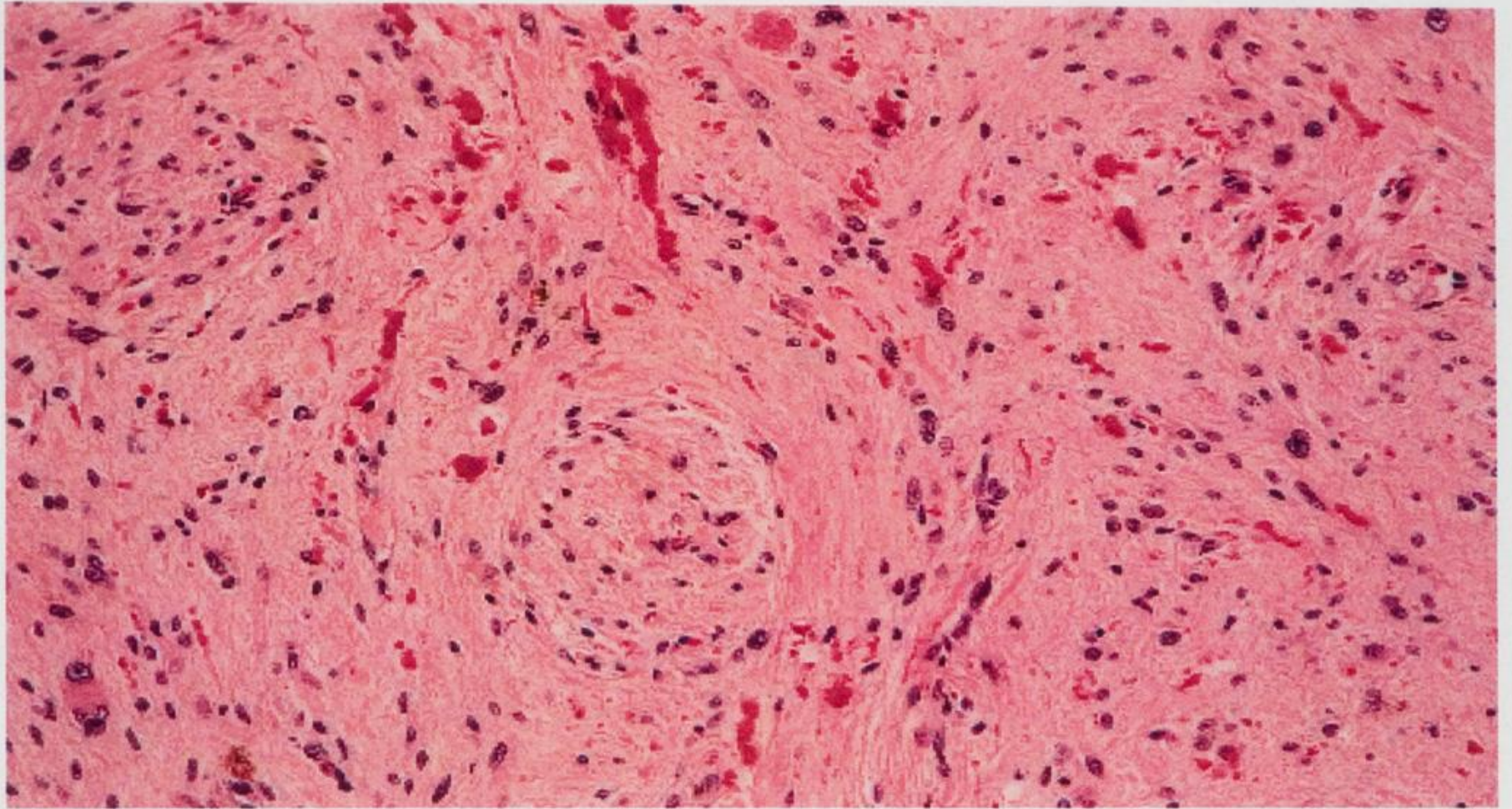
- 
- **Gross Description:** The unfixed brain weighs 1320 gm. A cerebral hemisphere with attached brainstem and cervical spinal cord is seen. The brain is remarkable grossly for a large tumor that appears to arise in the central pons. The brain has been sectioned in a mid-sagittal plane and shows the large tumor in the pons that measures approximately 4.0 x 3.0 x 3.0 cm in maximum extent.

- 
- **Microscopic Description:** A section of the tumor (B2) shows a well-differentiated neoplasm consisting of large, multipolar neurons that often show dysplastic features and a fibrillary background of neoplastic glial cells with mild to moderate cellularity and cellular pleomorphism. Rare mitotic figures are identified. There are no areas of necrosis.

- **Diagnosis:** Pilocytic astrocytoma (WHO grade I) of the pons, 4.0 x 3.0 x 3.0 cm.

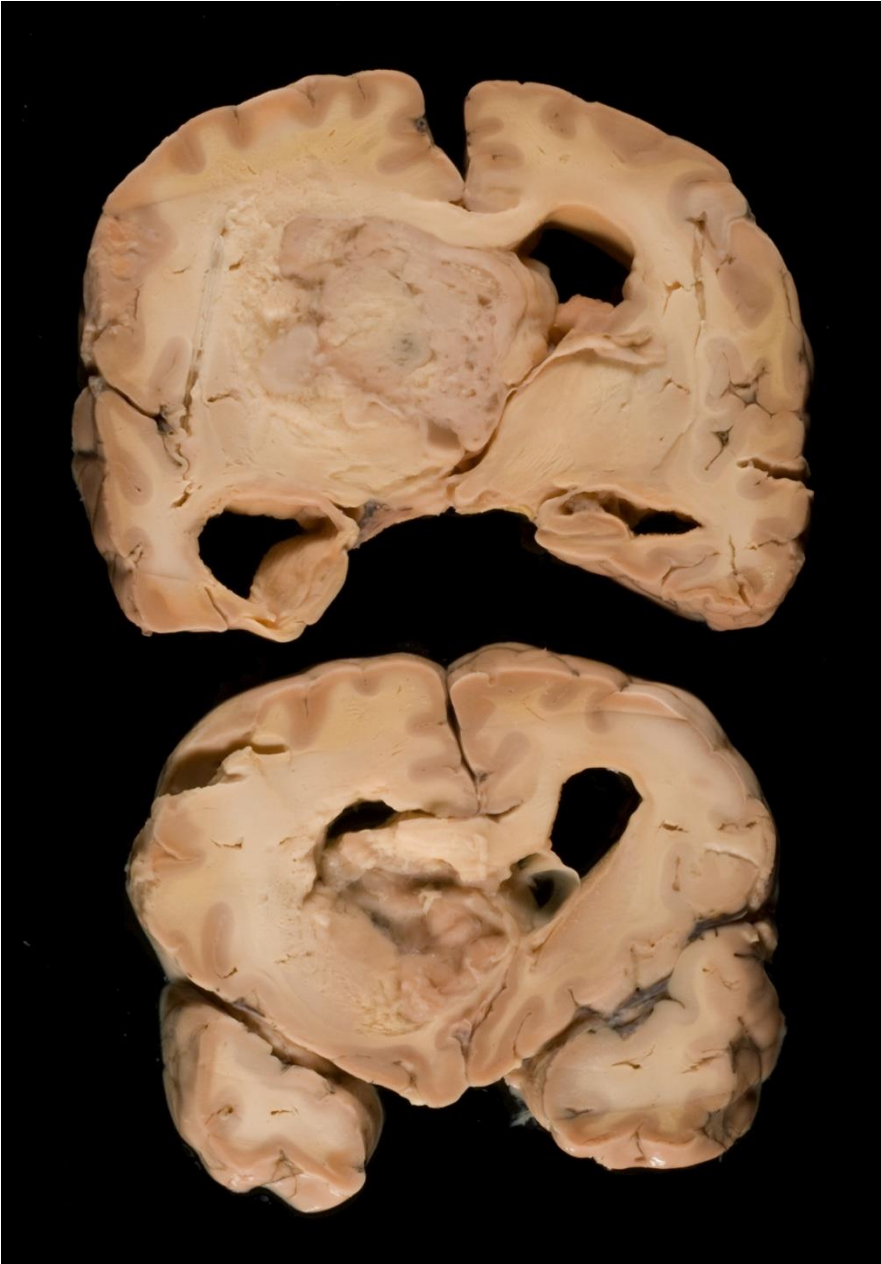



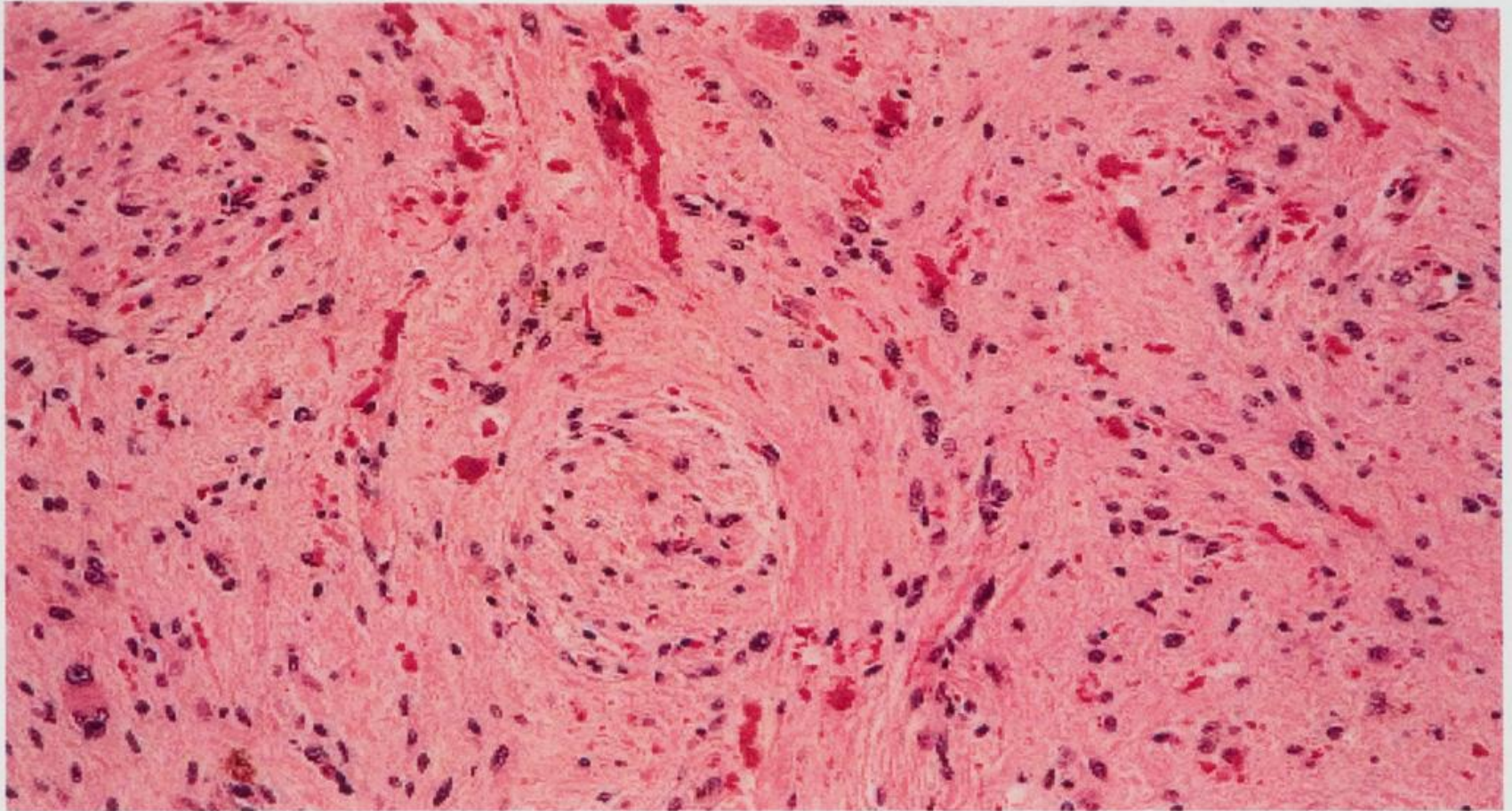


Astrocytoma

- **Case 11**
- **Clinical History:** This patient was a 55 year old white female who first came to medical attention four years prior to death when she was admitted to the psychiatry service for treatment of depression. Three years later she continued to experience severe depression but also complained of loss motor tone. The patient refused further medical treatment and developed increasing confusion and weakness. She subsequently died of pneumonia.
- **Gross Description:** The specimen consists two coronal sections of the brain. The corpus callosum is markedly enlarged. The tumor contains multiple small cysts. This is a coronal section of the brain taken at the level of the thalamus and hippocampus.
- **Microscopic Description:** Microscopically this tumor is composed of spindle shaped cells with elongated cytoplasmic processes. The tumor is not mitotically active and necrosis is not present.
- **Diagnosis:** Pilocytic astrocytoma of the frontoparietal lobe and corpus callosum



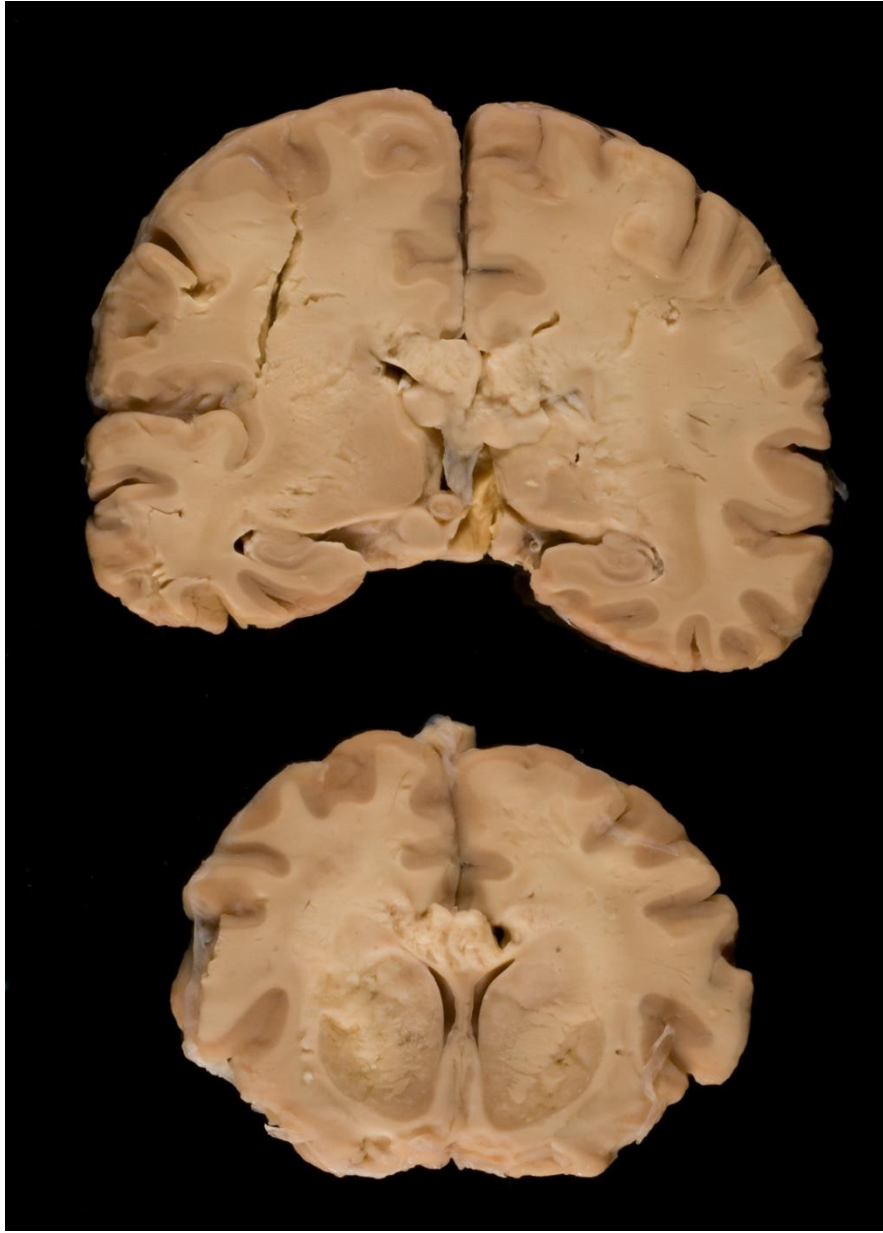



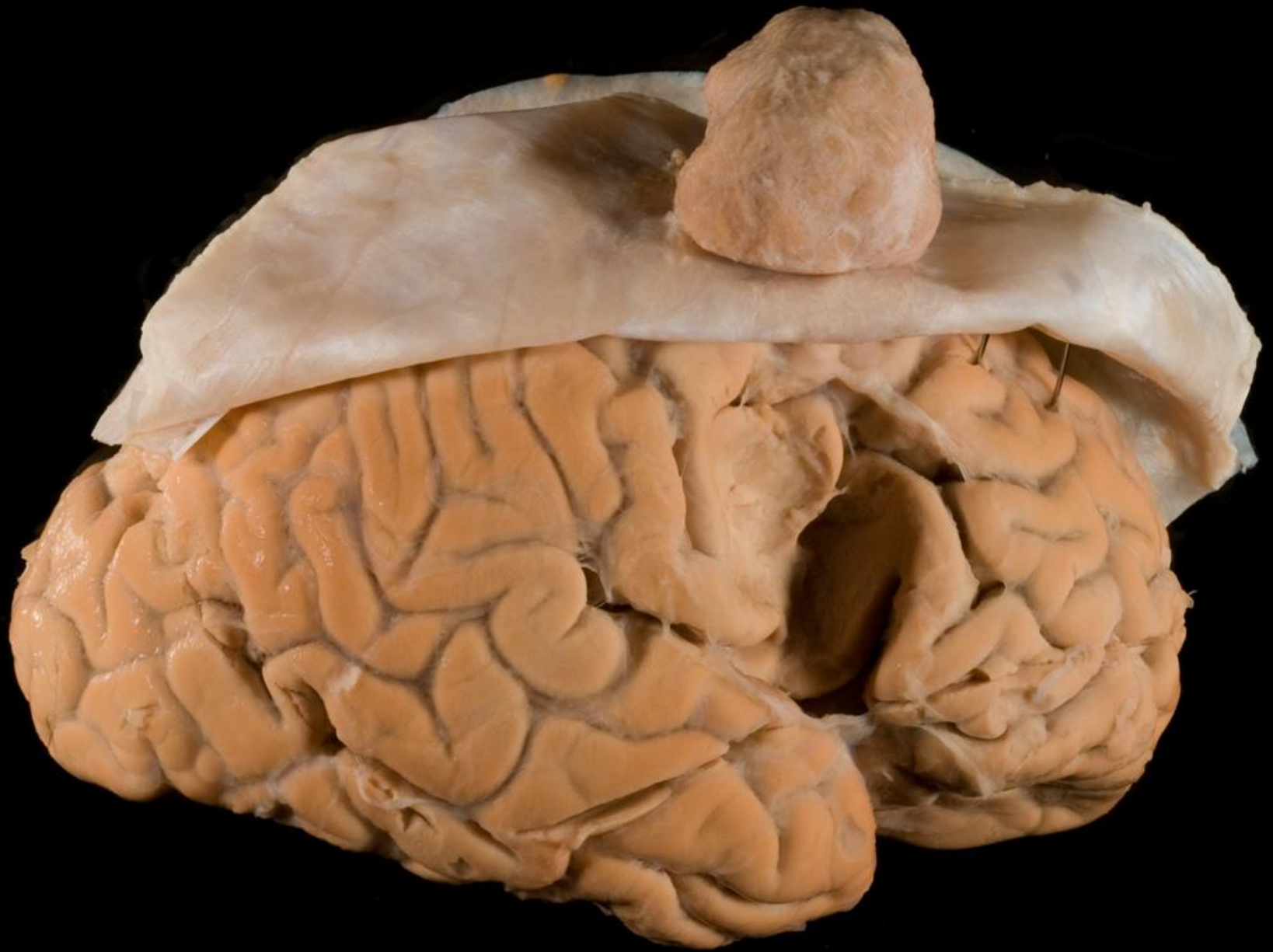
Astrocytoma

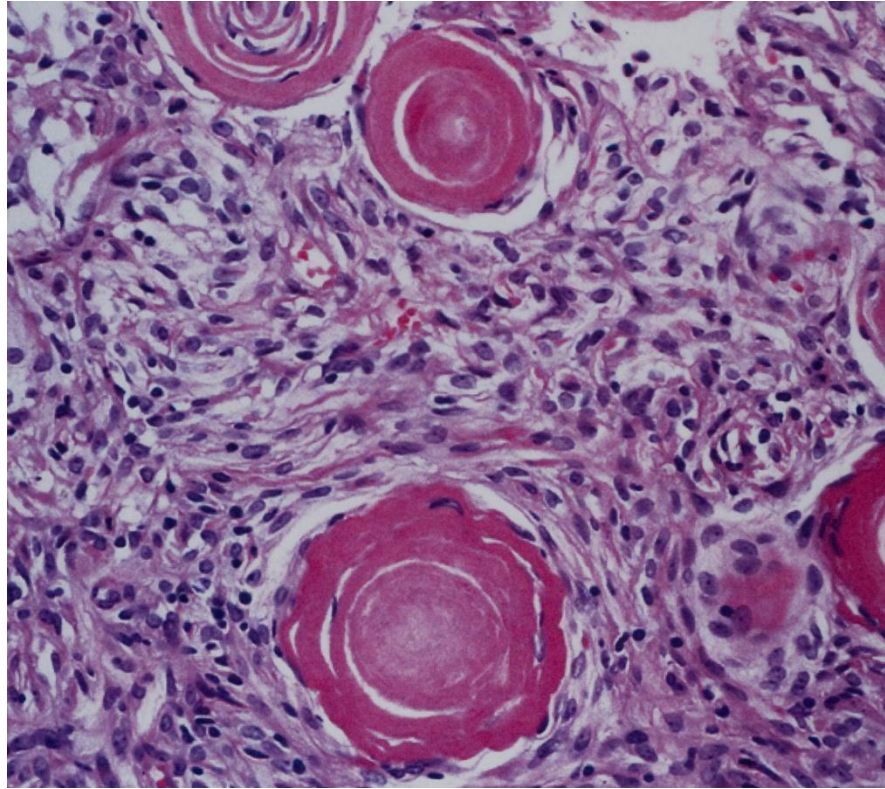
- **Case 12**
- **Clinical History:** The patient was a 10 year old African American female who experienced a generalized tonic clonic seizure. Upon presentation at the emergency room the patient's mother stated that she had complained of severe headache prior to the seizure. Further history from the mother revealed that the patient had a poor school performance. Neurological exam revealed bilateral papilledema with normal reflexes and no gait disturbance. There was a conjugate deviation of the eyes to the right. Magnetic resonance imaging revealed a large brain tumor. The patient expired six weeks after admission.
- **Gross Description:** Grossly, the gyri were flat and the sulci narrow. The specimen seen here consists of two coronal sections of cerebrum at the level of optic chiasm. There is a large tumor mass situated in the deep right frontal parietal region which is composed of necrotic yellow and gray tissue. The tumor protrudes into the right lateral ventricle and largely obscures the ventricle. The tumor has destroyed the basal ganglia and thalamus on the right. There is a striking mid-line shift of the cerebrum secondary to the tumor. Less obvious is the granular appearance of the ependyma in the left lateral ventricles. These multiple nodules are not directly connected to the main tumor mass. In addition to the findings observed here, other areas of the brain examined at autopsy disclosed multiple firm areas in the frontal and parietal regions.
- **Diagnosis:** Tuberosclerosis with giant cell glioblastoma.
- **Comment:** This tumor is called a glioblastoma because of its histologic appearance. However, it does not behave like a malignant tumor. It can be treated by simple surgical resection.





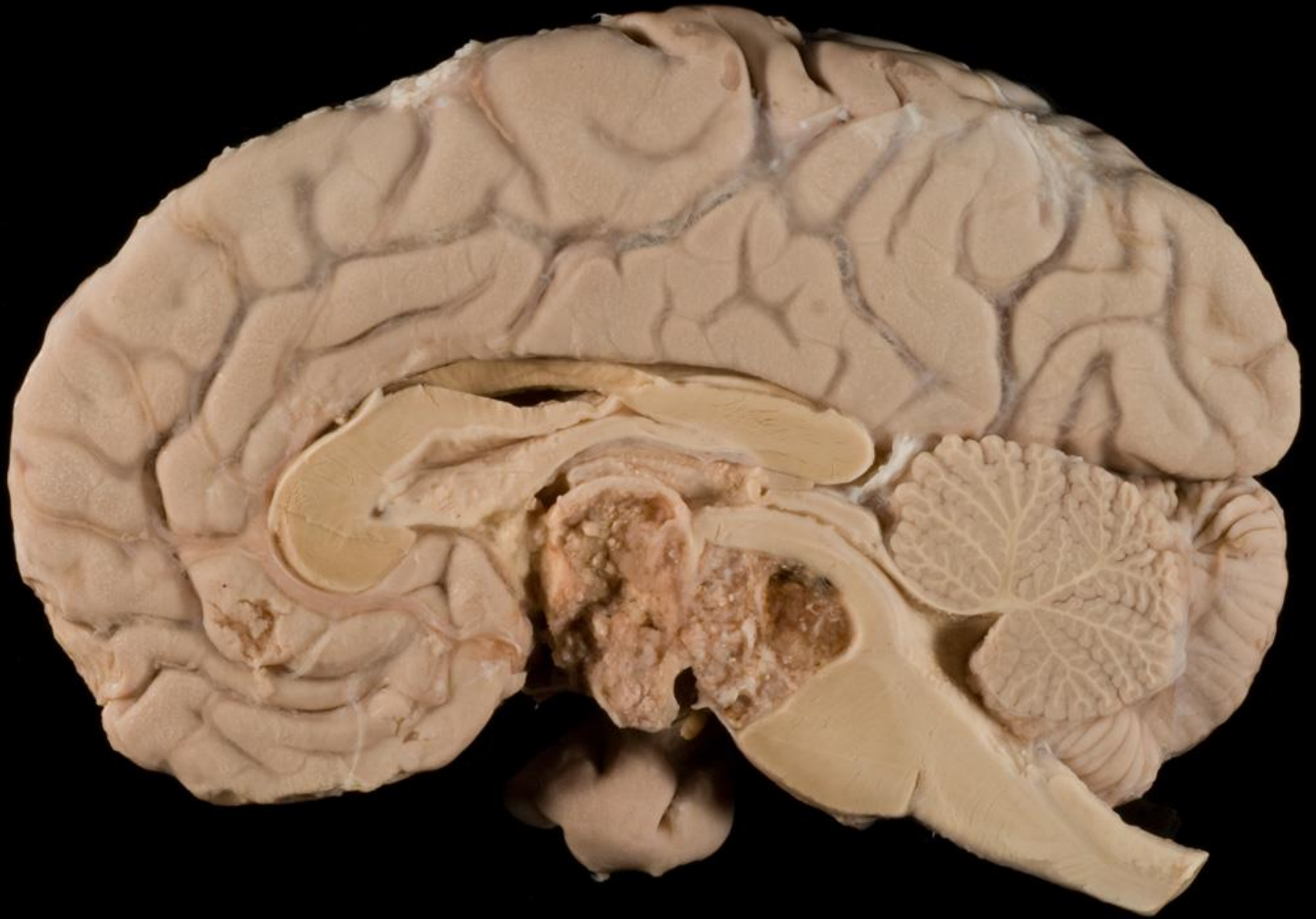- **Case 13**
- **Clinical History:** The patient was a 64 year old white female with a history of rheumatic heart disease and congestive heart failure. She did not have any central nervous systems complaints and died secondary to complications of her heart disease.
- **Gross Description:** The specimen represents an incidental finding at autopsy. There is a 4 x 3 x 3 cm hard partially calcified mass attached to the dura which projects into and compressed the right frontal cortex. The cerebral cortex has been indented but not invaded by the tumor.
- **Diagnosis:** Meningioma



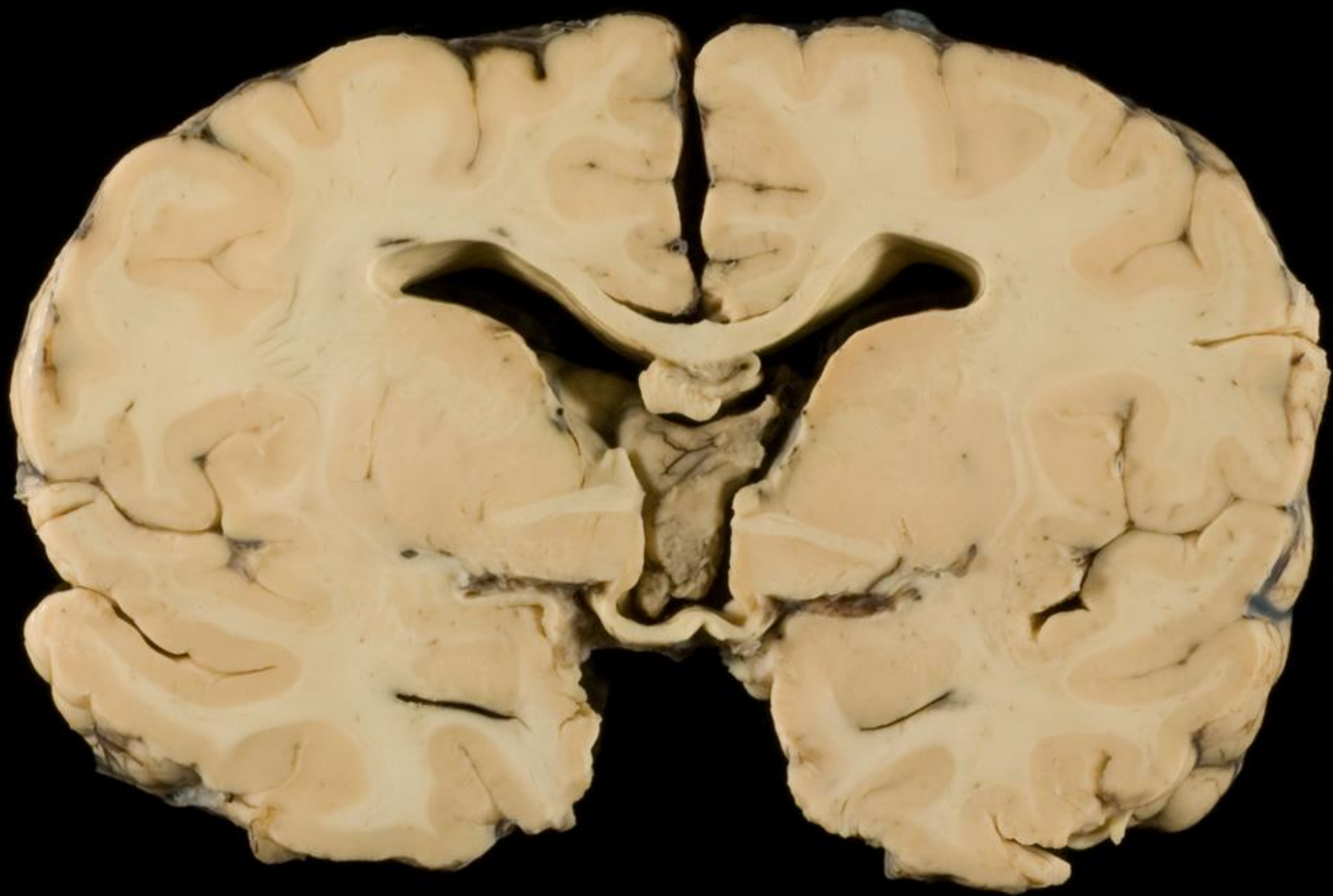


- **Case 14**
- **Clinical History:** This patient was a 73 year old African American who had vague complaints eight years prior to death. Five years prior to death he developed symptoms of hyperventilation and diabetes mellitus. Two weeks prior to death he developed weakness on the right side of his body. On physical exam the patient was obese. He had testicular atrophy and gynecomastia. Imaging studies revealed a tumor in the sella turcica.
- **Gross Description:** There is an irregular cystic tumor with an area of recent hemorrhage located in the region of the hypothalamus. It extends into the third ventricle and into the midbrain.
- **Diagnosis:** Craniopharyngioma





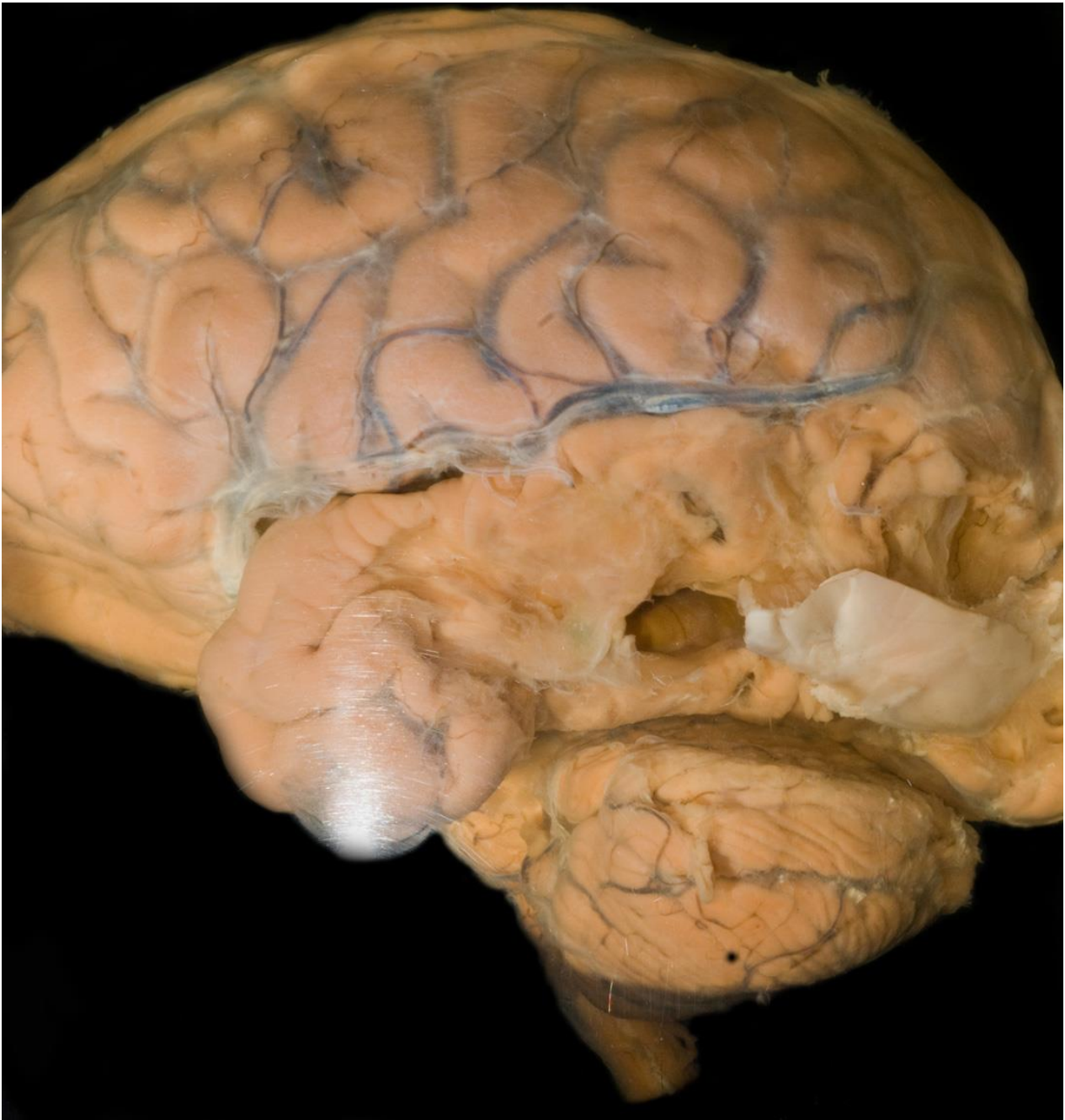- **Case 15**
- **Clinical History:** 14-year-old boy transferred from an outside hospital with hydrocephalus and cardiac arrest. While playing in the snow, he collapsed and was unresponsive. A brain CT demonstrated severe hydrocephalus and a suspected mass in the posterior fossa. On arrival to Duke University Medical Center, he was pulseless with active CPR being performed by EMS. Pupils were fixed and dilated to approximately 8 mm. There was no cough, no corneal, no gag reflex. He did not move any of his extremities to noxious stimuli. Neurosurgery inserted an external ventricular drain and cerebral spinal fluid came back under extremely high pressure, greater than 40 mm of water. He subsequently lost pulses and was pronounced dead.
- **GROSS DESCRIPTION:** The unfixed brain weighs 1254 grams. An intraventricular shunt is present. There is swelling and herniation of the brainstem and cerebellum. The brain is sectioned coronally. It is remarkable for a tumor which occupies the entirety of the third ventricle and is located in the region of the pineal gland. The tumor has a grayish color. The tumor measures approximately 4 x 1.5 x 1 cm in maximum extent. In addition, there is intraventricular hemorrhage which is worse on the left than on the right. There is severe ventricular dilation.
- **MICROSCOPIC DESCRIPTION:** Sections show a well differentiated pineocytoma. The cells are loosely coherent, monotonous with densely hyperchromatic nuclei and moderate lightly eosinophilic cytoplasm. There is mild nuclear pleomorphism. Mitotic figures are not seen. There is loose rosette formation.
- **DIAGNOSES:**
  - Pineocytoma, 4 x 1.5 x 1 cm with invasion of the left choroid plexus.
  - Status post intraventricular shunt placement,
  - Intraventricular hemorrhage moderate, left greater than right.
  - Cerebral edema with brainstem herniation



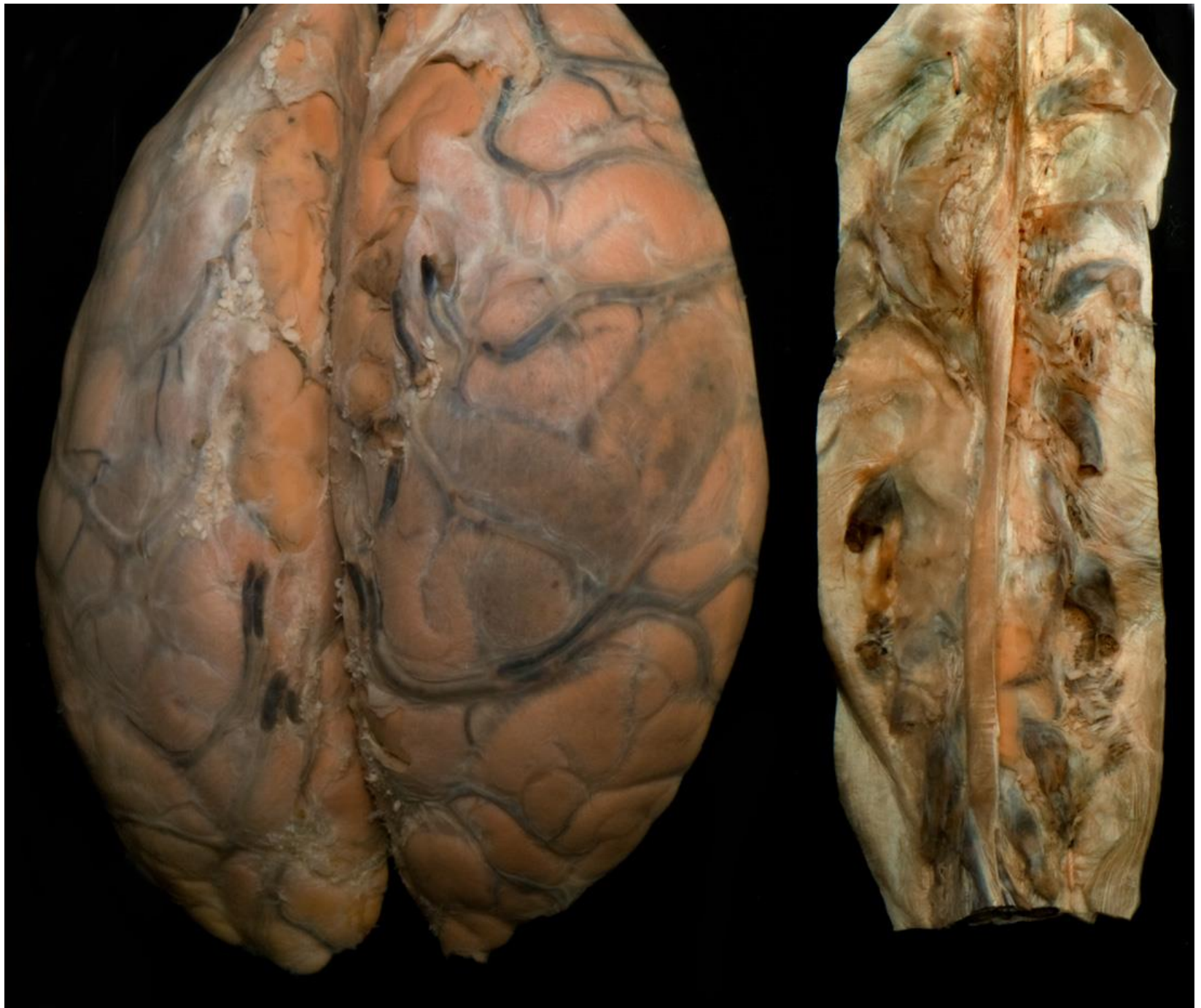**These specimens have been  
fixed and mounted  
professionally.**

- **Case M1**
- **CLINICAL HISTORY:** This was an adult male who 2 years prior to death suffered from a self-inflicted shotgun blast to the left side of his face and brain. After treatment he survived the acute episode; approximately one year later, the patient began to have seizures, which were progressive and unmanageable.
- **GROSS PATHOLOGIC DESCRIPTION:** This is the left hemisphere of the patient's brain. There is a large linear irregular defect extending from the left temporal lobe posteriorly to the occipital lobe. A portion of the dura has been carried into the parenchyma by the blast. This was the focus for seizure activity.
- **DIAGNOSIS:** Gunshot wound to the head, self-inflicted.



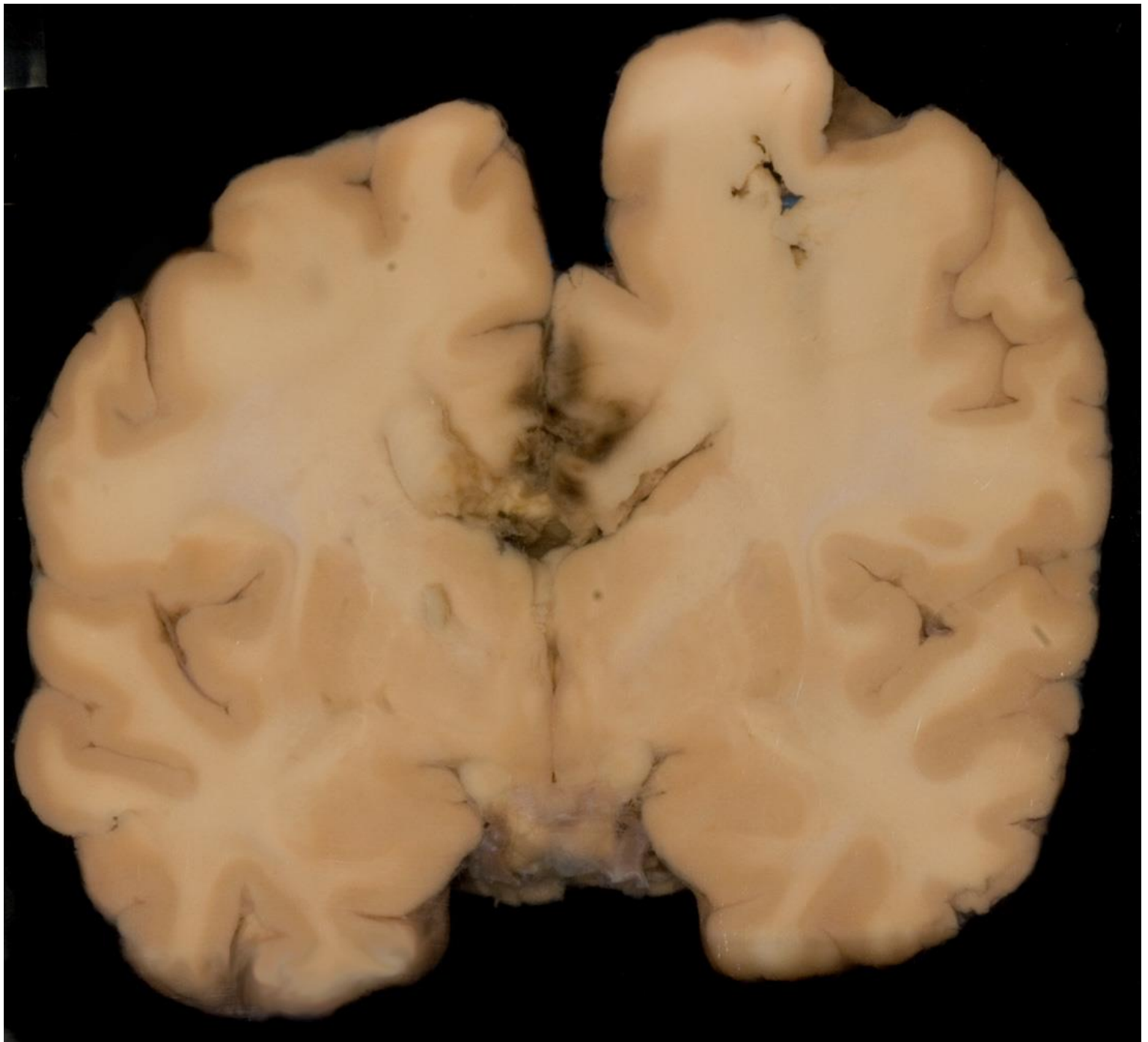


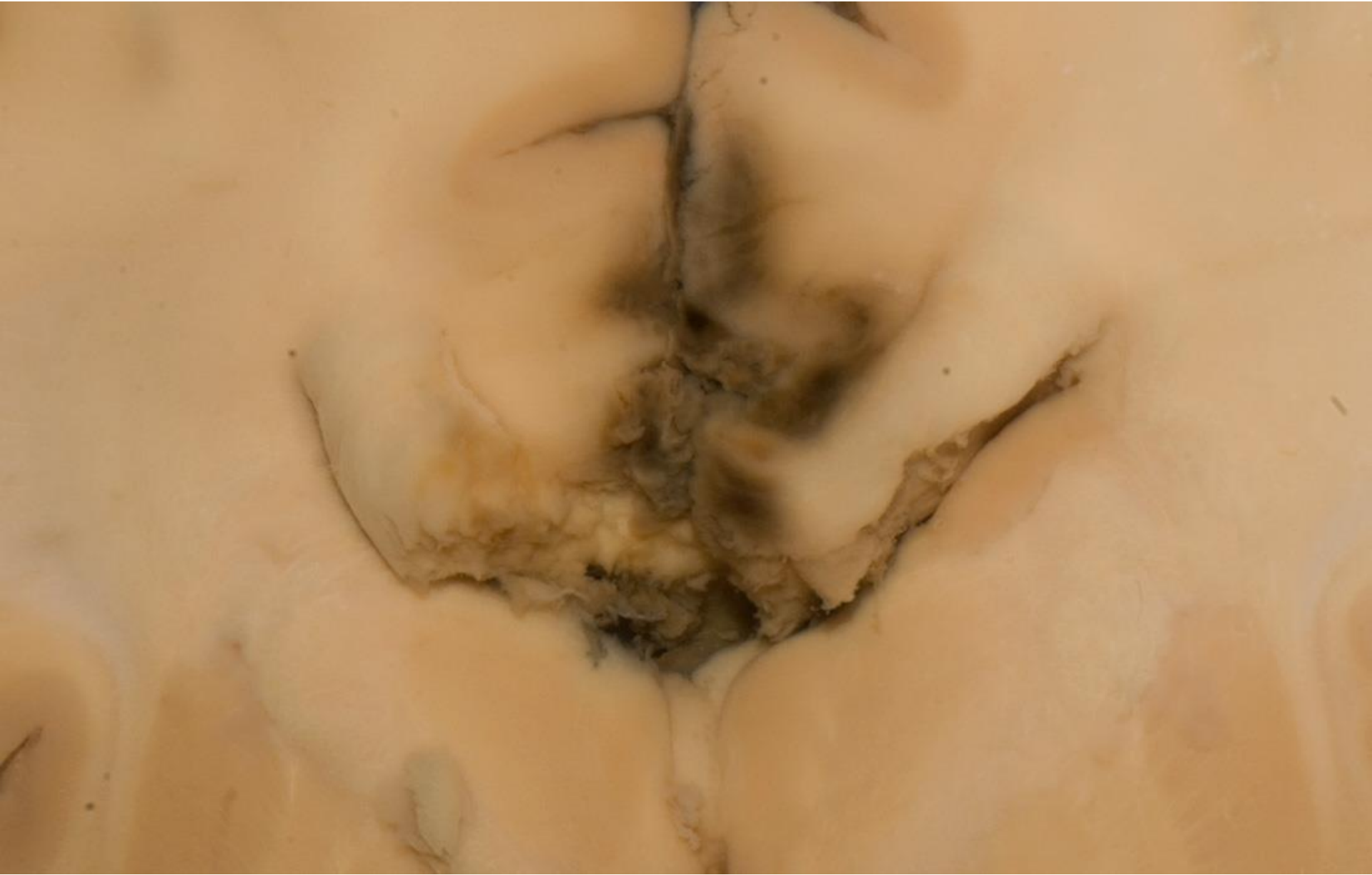- **Case M2**
- **CLINICAL HISTORY:** This was a 31 year old male who was admitted to Duke with a three week history of “flu like syndrome” with headaches and slight fever. Several days prior to his death, he had a focal seizure on the right side of his body. An arteriogram revealed cortical vein thrombosis with nonfilling of his superior sagittal sinus. On the day of his death, a member of the patient’s family was massaging his calf when he suddenly gripped his chest, gasped and expired.
- **GROSS PATHOLOGIC DESCRIPTION:** The patient expired due to multiple pulmonary emboli. The specimen consists of the superior two-thirds of the patient’s brain mounted in its entirety. Most of the dura, including the dura overlying the main dural sinuses, has been dissected away. The entire superior sagittal sinus, the right transverse sinus, and the right sigmoid sinus are distended with thrombus. Microscopically, the thrombus was moderately well-organized, with well-defined endothelialized recanalization.
- **DIAGNOSIS:** Thrombosis of the superior sagittal sinus with extension into the right transverse and sigmoid sinuses, and the right internal jugular vein.
- **COMMENT:** The cortical veins drain into the superior sagittal sinus. From a pathological point of view, dural sinus thrombosis can be primary or secondary. Primary dural sinus thrombosis is quite rare, and when it occurs, is usually associated with clinical conditions which predispose to an abnormal coagulability such as Factor V Leiden, pregnancy, dehydration, cachexia, fever, or sickle cell anemia. Secondary or septic sinus thrombosis is secondary to infections either in a remote area or near the sinus. Septic dural sinus thrombosis is associated with acute inflammation such as septic thrombosis of the transverse sinus which may follow untreated mastoiditis.



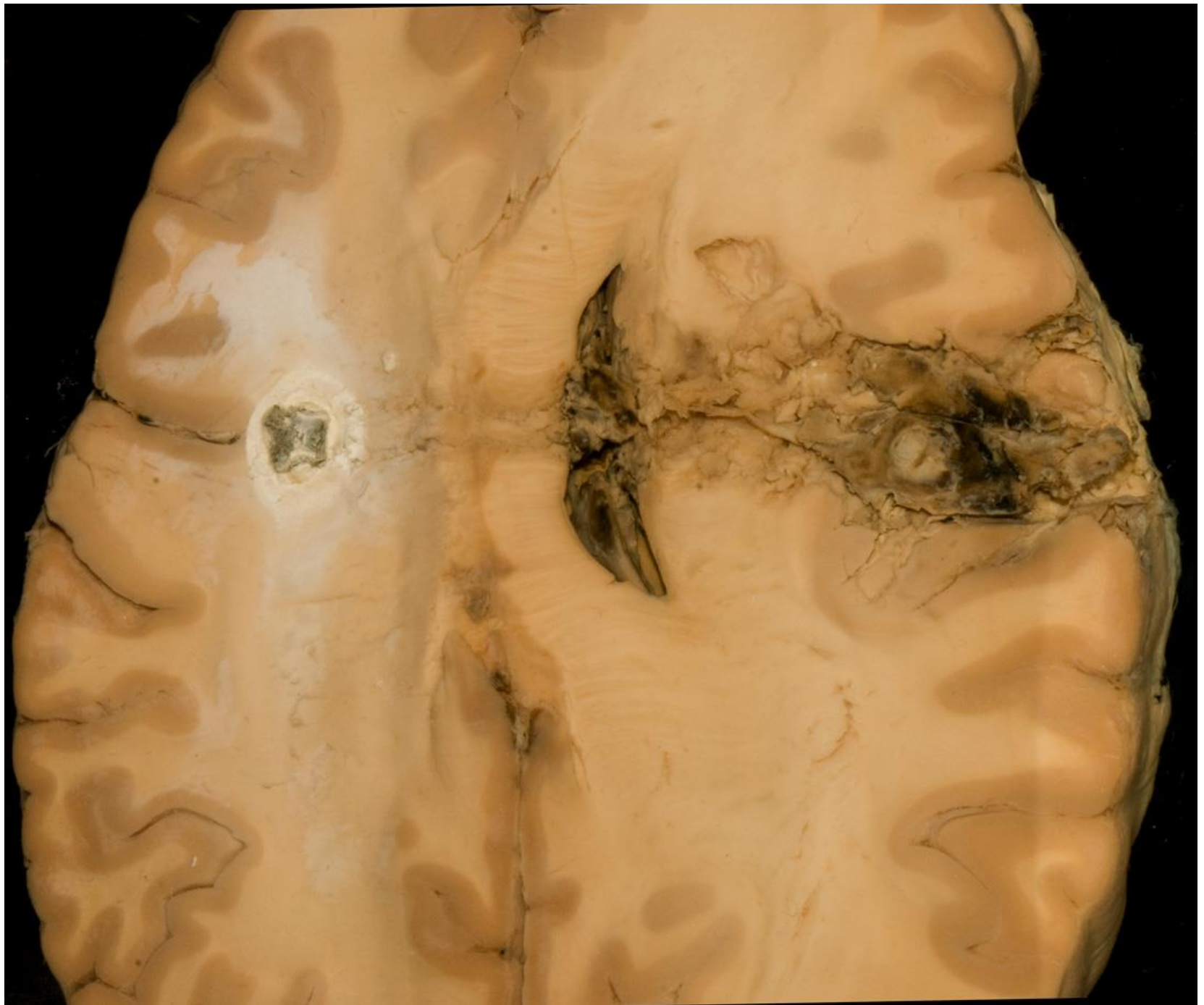
- **Case M3**
- **CLINICAL HISTORY:** This was a 35 year old male who was admitted to the Emergency Room after having been in an automobile accident. At the time of admission, the patient was in a coma, but bilateral equal papillary reaction and doll's eyes movements were present. Fundi were clear. A left hemiparesis as well as a possible Babinski on the left side were noted. His hospital course was one of progressive deterioration. He became less responsive and progressed in a deeper coma. By the fourth hospital day the patient was in a deep coma with fixed and dilated pupils, and EEG showed that there was no cortical activity. He was pronounced dead on the fourth hospital day.
- **GROSS PATHOLOGIC DESCRIPTION:** There is moderate amount of subarachnoid hemorrhage. The corpus callosum has been severed, and the surrounding portions of the cingulate gyrus are necrotic and have a hemorrhagic discoloration. The white matter is not clearly demarcated from the gray matter. In addition, multiple secondary brain stem hemorrhages were noted at the time of autopsy.
- **DIAGNOSIS:** Cingulate gyrus contusion and severance of the corpus callosum.





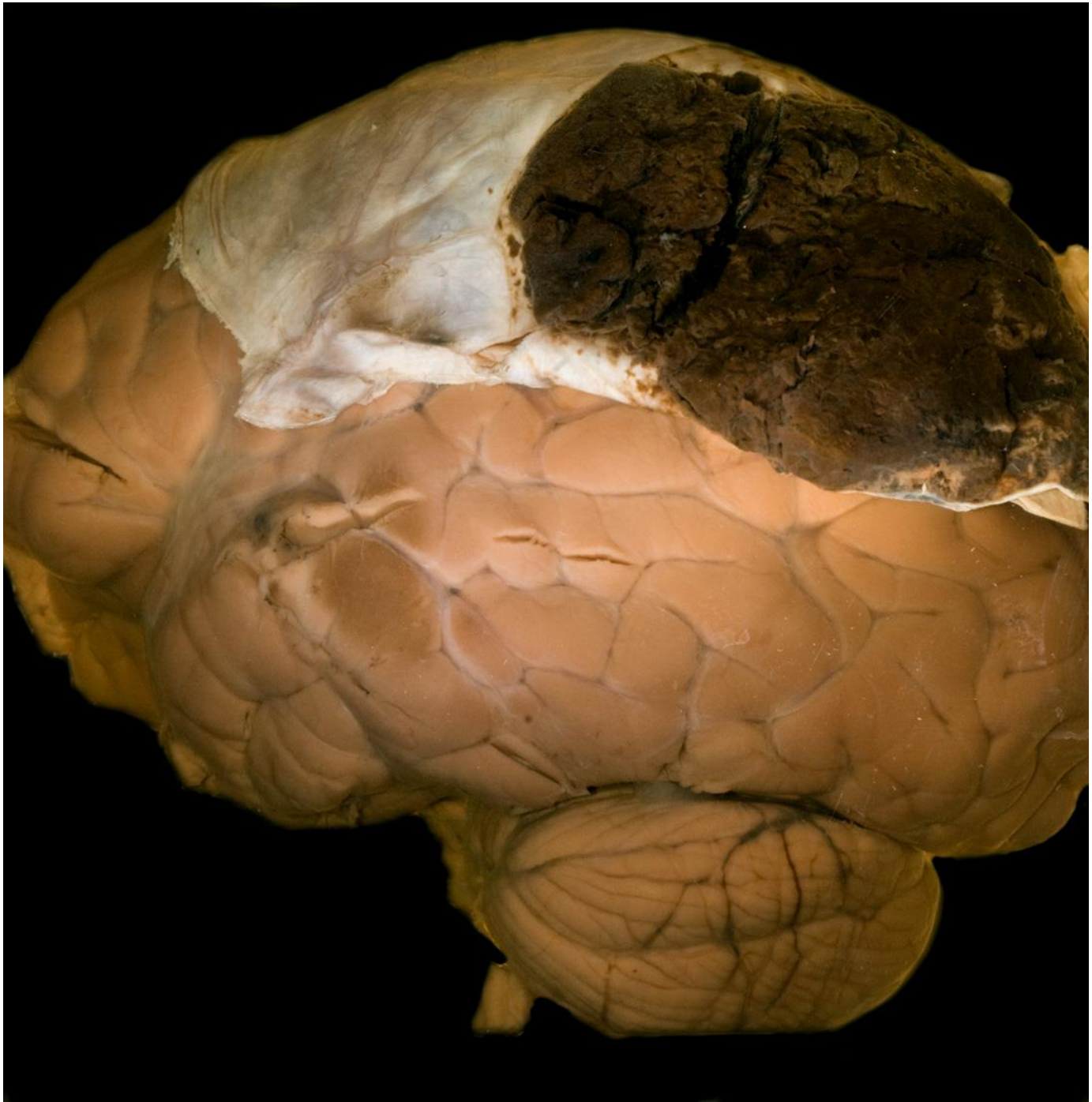

- **Case M4**
- **CLINICAL HISTORY:** This was a 42 year old male who was admitted 45 minutes prior to death with an apparent self-inflicted gunshot wound to the head. At the time of his admission, the patient's pupils were fixed and dilated. His blood pressure was very low and the patient subsequently expired.
- **GROSS PATHOLOGIC DESCRIPTION:** This is a transverse section of the patient's cerebral hemispheres. The entrance wound and the tract of a bullet can be seen coursing from the right cerebral cortex into the brain and across the midline, with the bullet lodging in the left cerebral hemisphere. The bullet traversed the right lateral ventricle, causing massive intraventricular hemorrhage. In addition, secondary brain stem hemorrhages were present.
- **DIAGNOSIS:** Gunshot wound to the cerebral hemispheres.

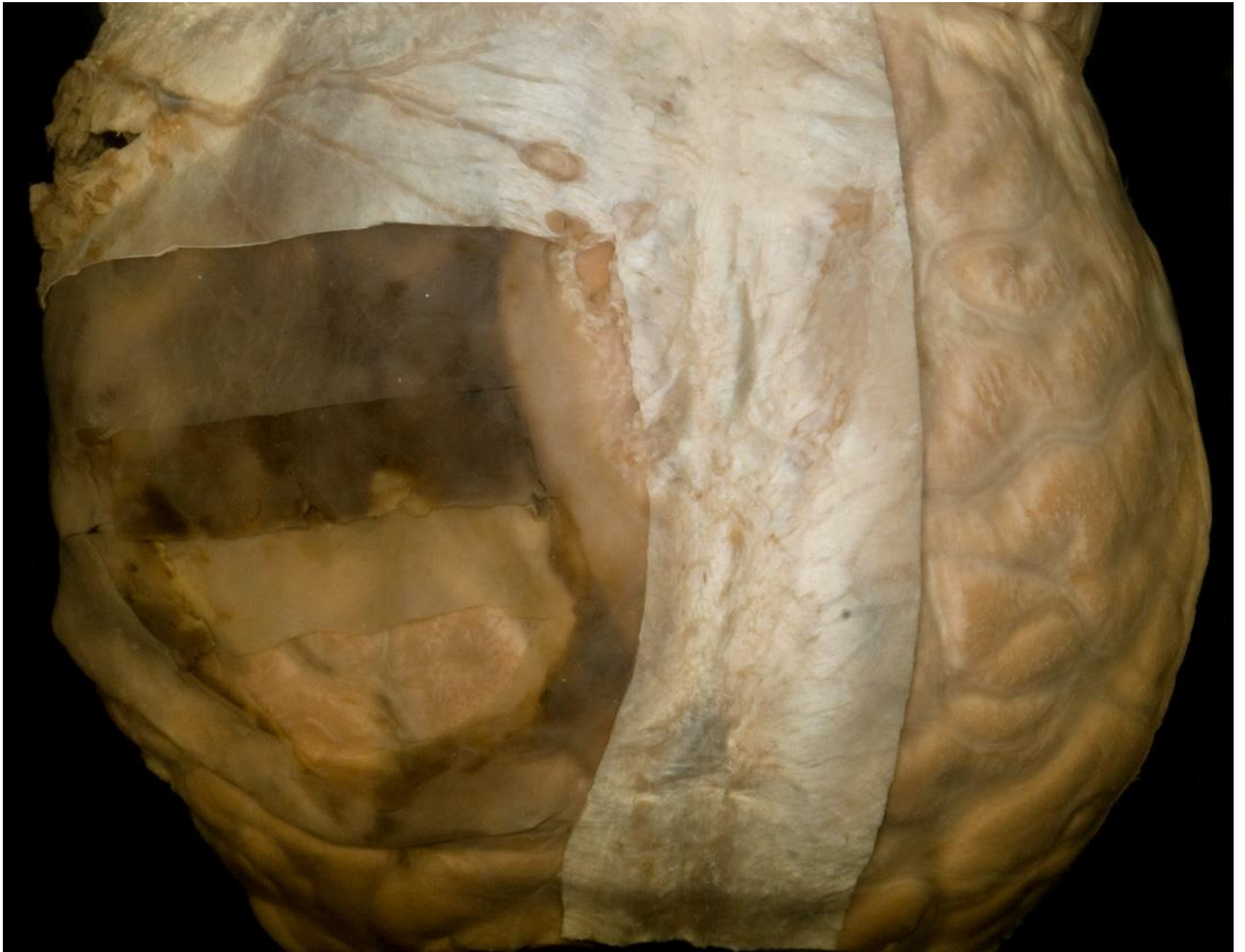




- **Case M5**
- **CLINICAL HISTORY:** This was 15 year old male who fell out of a truck, striking his head on a sign post. There was no period of unconsciousness. Twenty four hours later, the patient began to develop progressive lethargy, vertigo, headache, and vomiting. He was sent to Duke for evaluation, where he had a cardiac arrest while being evaluated by neuroradiology. Resuscitation efforts were unsuccessful.
- **GROSS PATHOLOGIC DESCRIPTION:** A large epidural blood clot is located over the left parieto-occipital area with compression of the underlying brain. There was a fracture of the posterior parietal area of the skull.
- **DIAGNOSIS:** Left parietal epidural hematoma
- **COMMENT:** An epidural hematoma must always be considered when there has been trauma to the head associated with skull fracture. The classical history of the development of epidural hematoma is that of trauma to one side of the head, followed by a brief period of unconsciousness, which in turn is followed by a so-called “lucid” interval of 2 to 24 hours. After that time, the patient deteriorates rapidly, with the onset of a marked change in level of consciousness and later pupillary signs suggestive of incipient transtentorial herniation. The cause of death in most cases of epidural hematoma is transtentorial herniation of the medial portion of the temporal lobe, with compression of the third nerve and posterior cerebral artery. Unilateral dilation of a pupil in a clinical setting similar to the above should always suggest the onset of uncal herniation. The contra lateral cerebral peduncle of the midbrain is often compressed against the notch of the tentorium, giving rise to hemiparesis on the same side of the lesion, which is a false localizing sign. Compression of the cerebral peduncle against the tentorium is called Kernohans’ notch. Once transtentorial herniation has progressed, secondary midbrain hemorrhages occur, with death soon after from respiratory arrest.

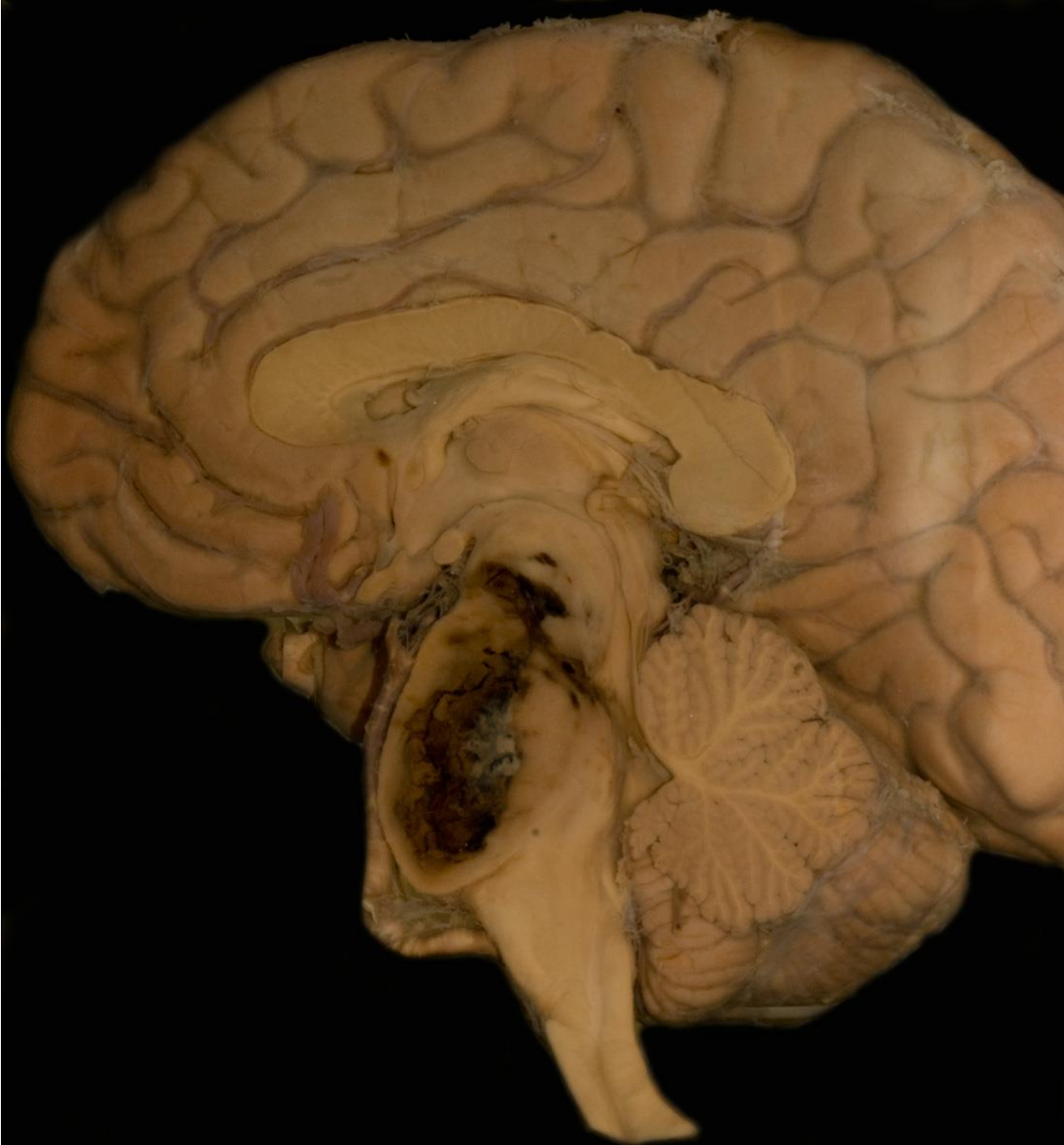

- **Case M6**
- **CLINICAL HISTORY:** This was a 64 year old male who was admitted with a one week history of right-sided weakness, generalized headache, confusion, and disorientation. Neurological exam revealed a fluctuating level of consciousness, blurring of the left optic disc, and a right hemiparesis. Following left carotid arteriogram, the patient was taken to surgery. Postoperatively, he improved slightly before deteriorating progressively, and in spite of further operative intervention, he expired on the eleventh hospital day. His wife stated that the patient fell and struck his head three months prior to the onset of his difficulties, but there were no immediate sequelae.
- **GROSS PATHOLOGIC DESCRIPTION:** A large subdural hematoma covers the entire left cerebral hemisphere. The brain stem was displaced from left to right and the left uncus had herniated through the tentorial notch. The chronicity of the subdural hematoma is suggested by the fact that there is well developed pseudomembrane formation. The cause of death was compression of the brain stem secondary to the expanding subdural hematoma over the left cerebral hemisphere.
- **DIAGNOSIS:** Subdural hematoma, chronic.

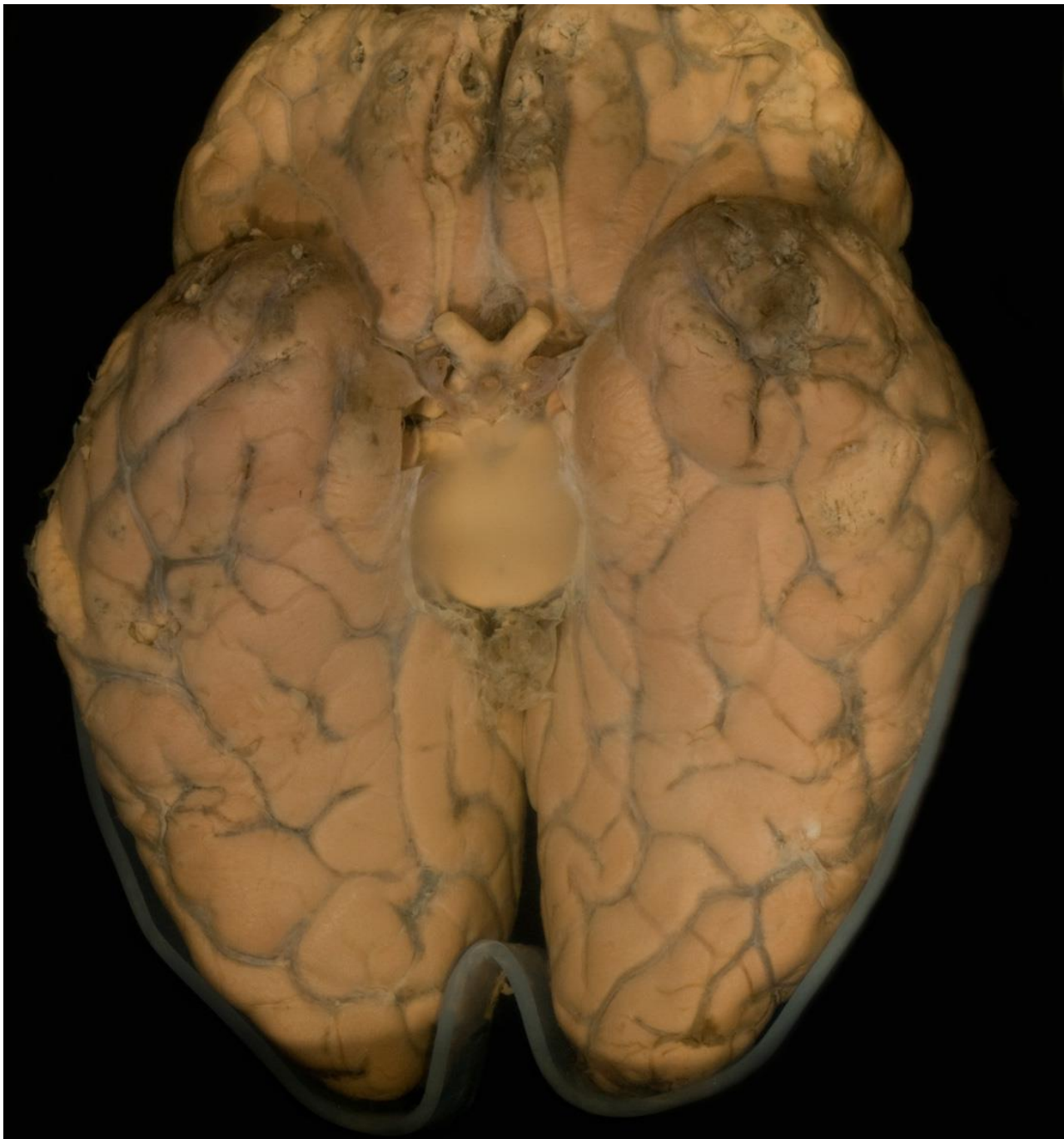

- **Case M7**
- **CLINICAL HISTORY:** This was a 42 year old male who was brought to the V.A. Emergency Room in a cyanotic condition without blood pressure or pulse. A note from an outside physician stated that the patient had a “convulsive episode” two hours earlier. Resuscitative efforts were unsuccessful. Past medical history included an admission to the V.A. Hospital in Durham three years prior to his death with accelerated hypertension and progressive renal dysfunction. His blood pressure during that hospitalization was 240/160.
- **GROSS PATHOLOGIC DESCRIPTION:** There is a massive hemorrhage into the pons. A moderate amount of subarachnoid hemorrhage is present. There is moderate atherosclerosis of the basilar artery.
- **DIAGNOSIS:** Hypertensive hemorrhage, pons.

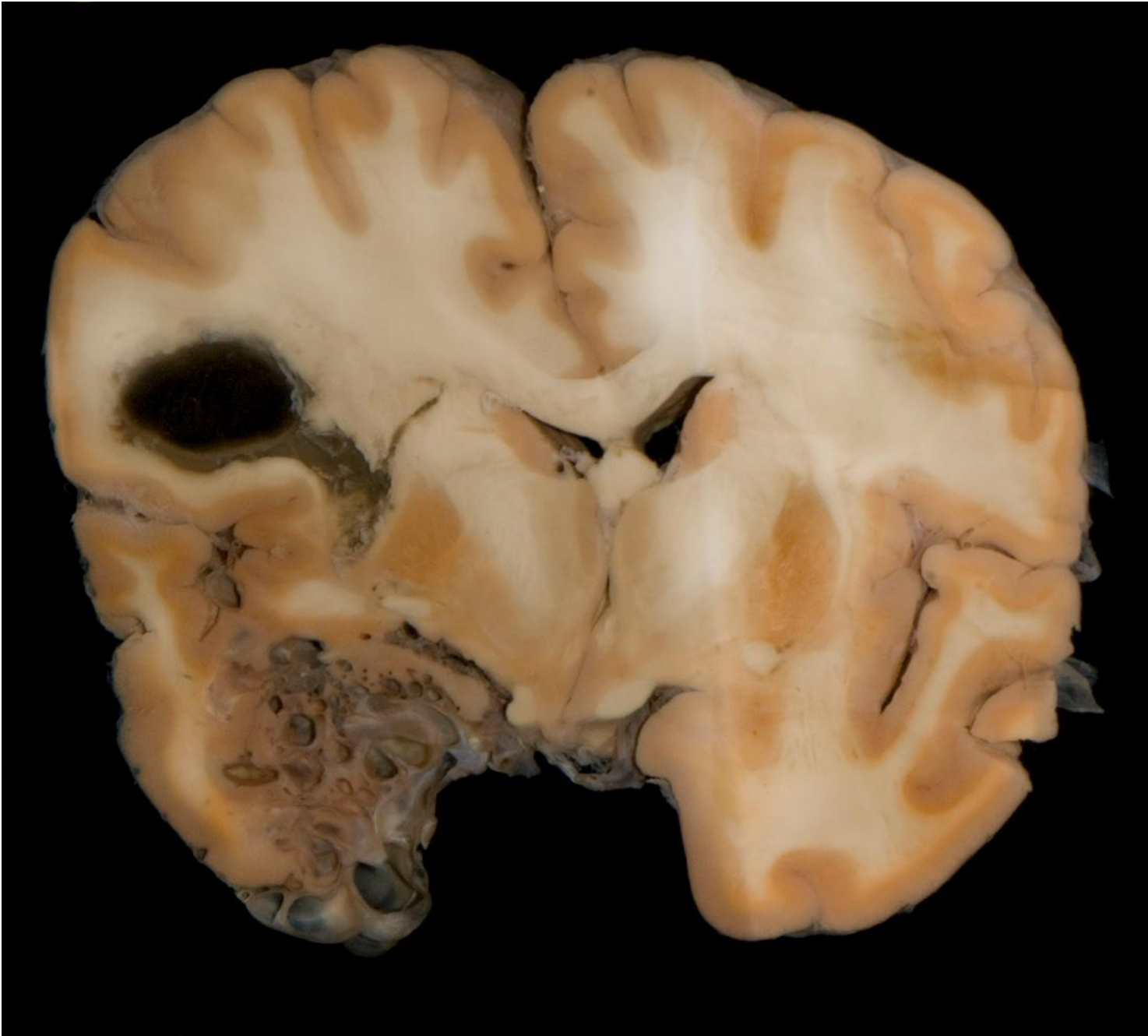




- **Case M8**
- **CLINICAL HISTORY:** This was a 54 year old male with a 14 month history of squamous carcinoma of the right main stem bronchus, for which he had a pneumonectomy. Following this pneumonectomy he developed right-sided empyema. During this hospitalization he developed a seizure and a cardiac arrest, from which he was resuscitated. He presented to the V.A. Hospital with severe shortness of breath 17 days prior to death. He had had occasional seizures for the last several years of his life.
- **GROSS PATHOLOGIC DESCRIPTION:** This is a view of the undersurface of the patient's brain. There are old, depressed, hemosiderin-stained defects on the anterior and medial portions of both temporal lobes, and on the anterior-inferior portions of the frontal lobes.
- **DIAGNOSIS:** Old contusions, frontal and temporal lobes.
- **COMMENT:** Old contusions such as these are often seen in chronic alcoholics and are frequently implicated as epileptogenic foci.

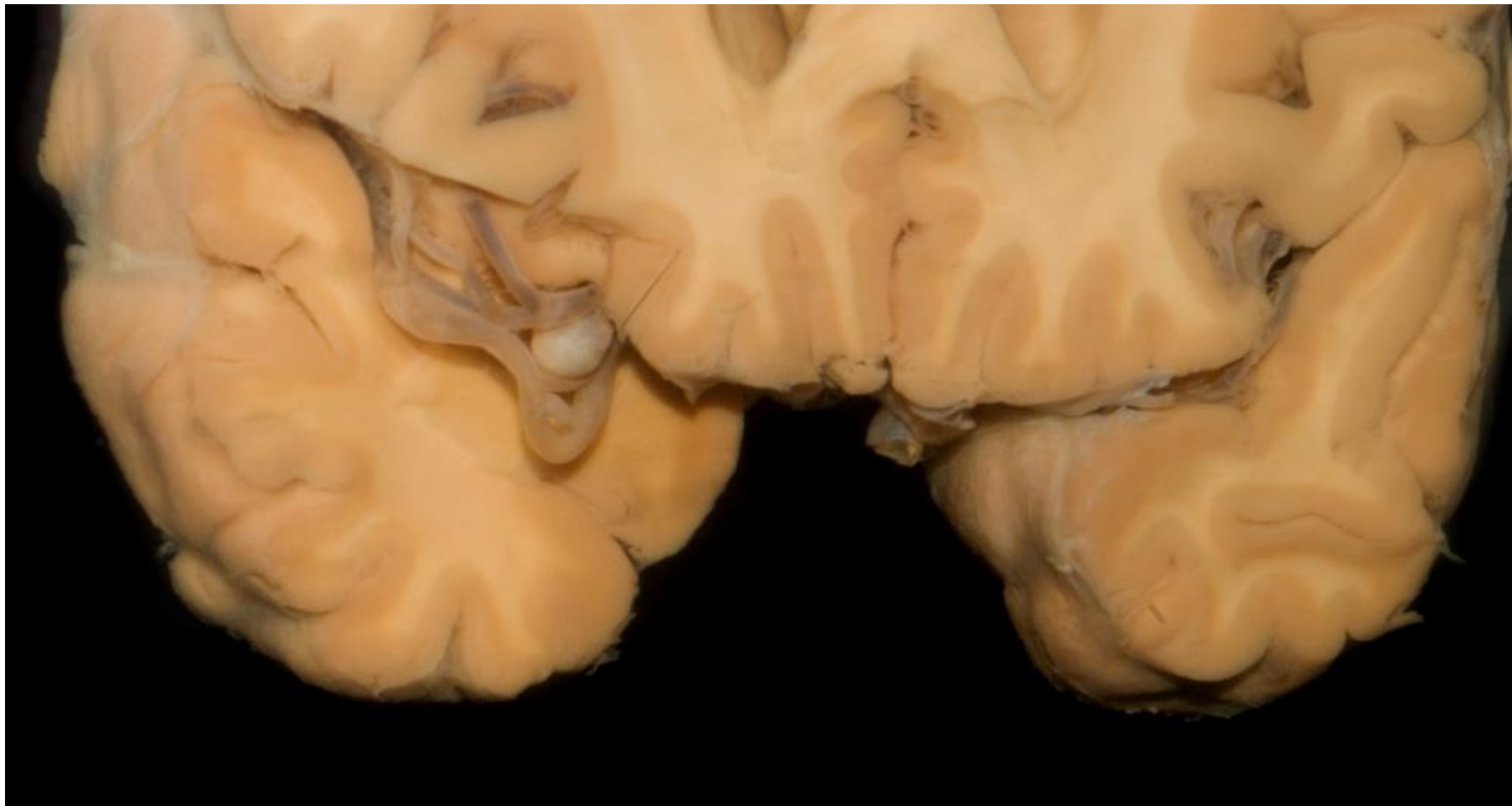

- **Case M9**
- **CLINICAL HISTORY:** This 54 year old male with a three week history of transient right sided numbness and severe bifrontal headaches developed a right hemiparesis, disorientation, and progressive obtundation. When his wife was unable to awaken him the next morning, she brought him to DUMC. He was comatose with non-reactive pupils and absent oculocephalic reflexes. The etiology of his condition was apparent on cerebral angiography. He remained unchanged until he died five days later.
- **GROSS PATHOLOGIC DESCRIPTION:** A large arterial-venous malformation occupies much of the tip of the left temporal lobe. It is directly fed off the enlarged left middle cerebral artery and is marked by dilated vascular channels several centimeters in diameter. Within the posterior frontal and anterior parietal lobe on the left is a 4 x 5 x 3 cm hematoma. Anteriorly it is not contiguous with the vascular anomaly, but posteriorly within the parietal lobe it was seen to arise from a large ruptured feeding vessel. The expanding nature of the hematoma is evidenced by left uncal herniation with distortion of the midbrain and small secondary hemorrhages.
- **DIAGNOSIS:** Arteriovenous malformation, left temporal lobe, with rupture and intracerebral hematoma left fronto parietal region.

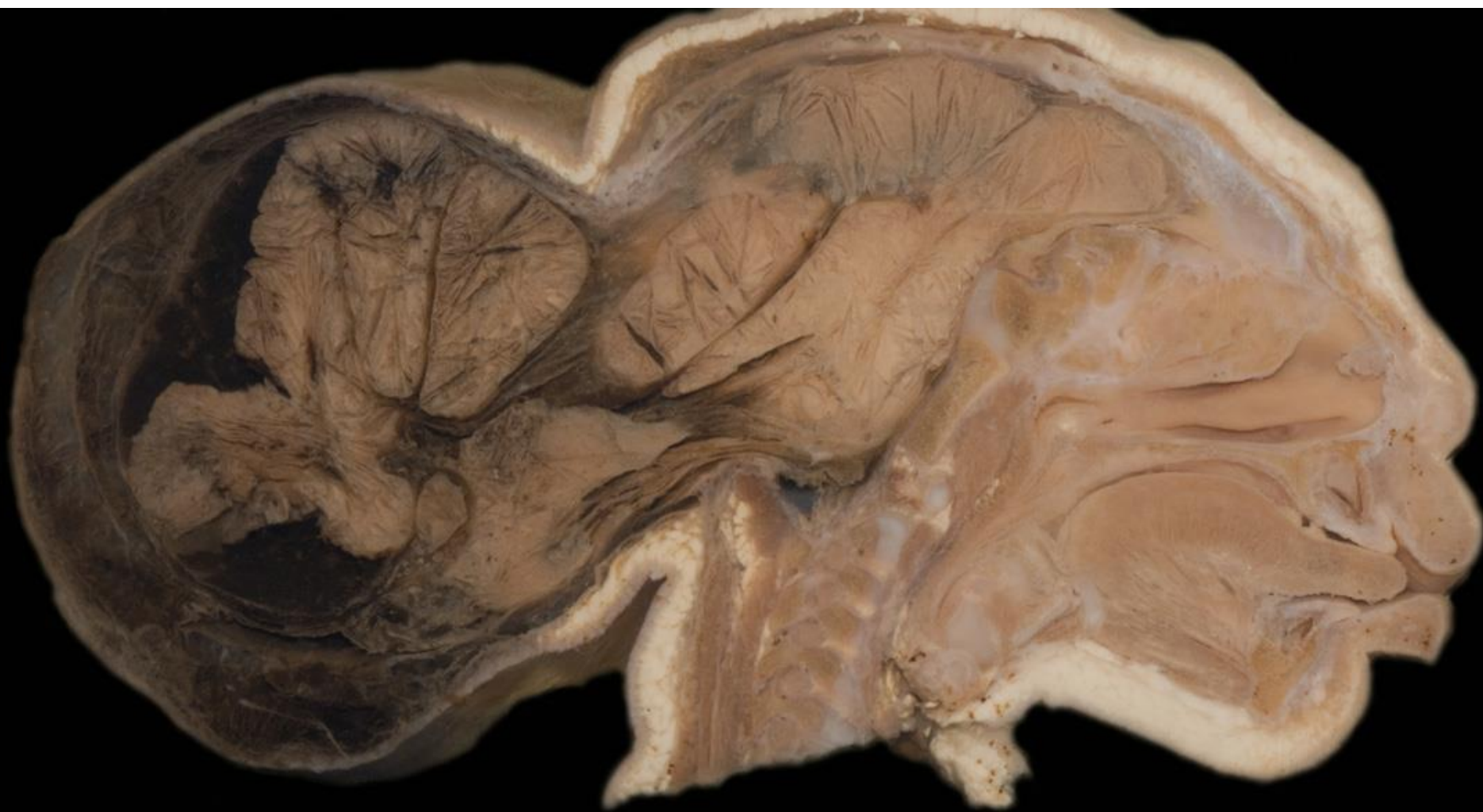




- **Case M10**
- **CLINICAL HISTORY:** This was a 68 year old male who several months prior to death presented with dysphasia, anorexia, severe weight loss, and mental confusion. Physical exam at the time revealed normal vital signs, a normal neurological exam, and wheezing. He was admitted to the hospital several weeks later, and in the hospital he had a progressive downhill course with increasing mental confusion. The patient expired during the fourth hospital week.
- **GROSS PATHOLOGIC DESCRIPTION:** The cause of death in this patient was adenocarcinoma of the right lung which had metastasized throughout his body. The specimen consists of a coronal section of the patient's brain with portion of the right temporal lobe dissected away. A small berry aneurysm at the trifurcation of the middle cerebral artery is seen. This was an asymptomatic aneurysm and was an incidental finding at autopsy.
- **DIAGNOSIS:** Berry aneurysm, trifurcation of the right middle cerebral artery.

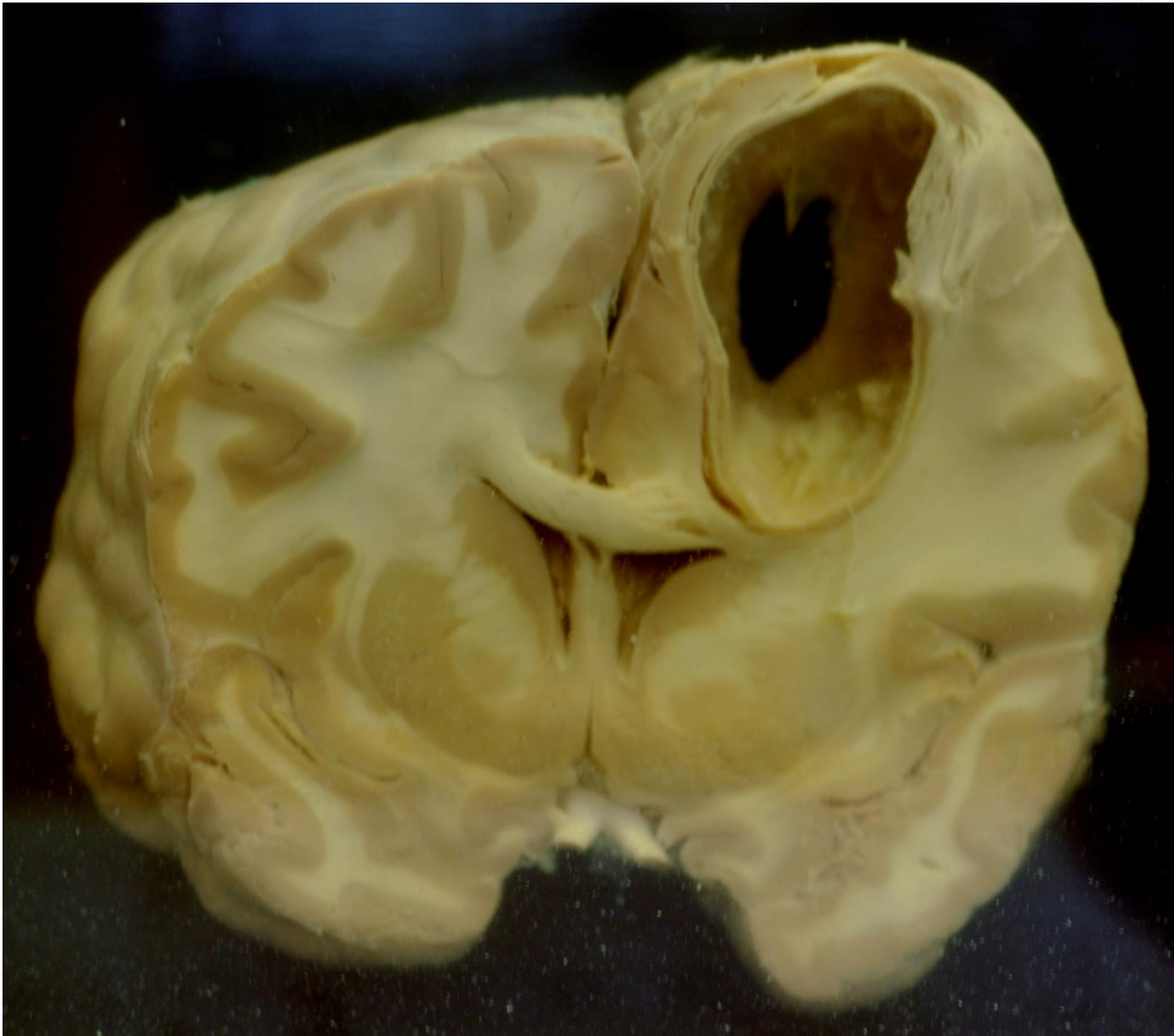


- **Case M11**
- **Clinical History** A term infant was delivered to 18 year old primigravida with minimal prenatal care. The infant developed meningitis expired soon after delivery.
- **Gross Description:** Part of the CNS herniates through a cranial defect.
- **Comment:** Encephaloceles represent approximately 10-15% of all neural tube defects. Their etiology and pathogenesis is poorly understood. Occipital encephaloceles, are the most common in North America (80%), and are easily diagnosed at birth. While routine use of ultrasound has been helpful in the prenatal diagnosis, maternal alpha-fetoprotein levels are often normal since the lesions are usually completely epithelialized and hence do not leak CSF. A poor prognosis and limited neurological functional capacity can be expected with significant encephaloceles such as this one. Corrective or palliative surgery is often of little benefit.
- **DIAGNOSIS :** Occipital Encephalocele

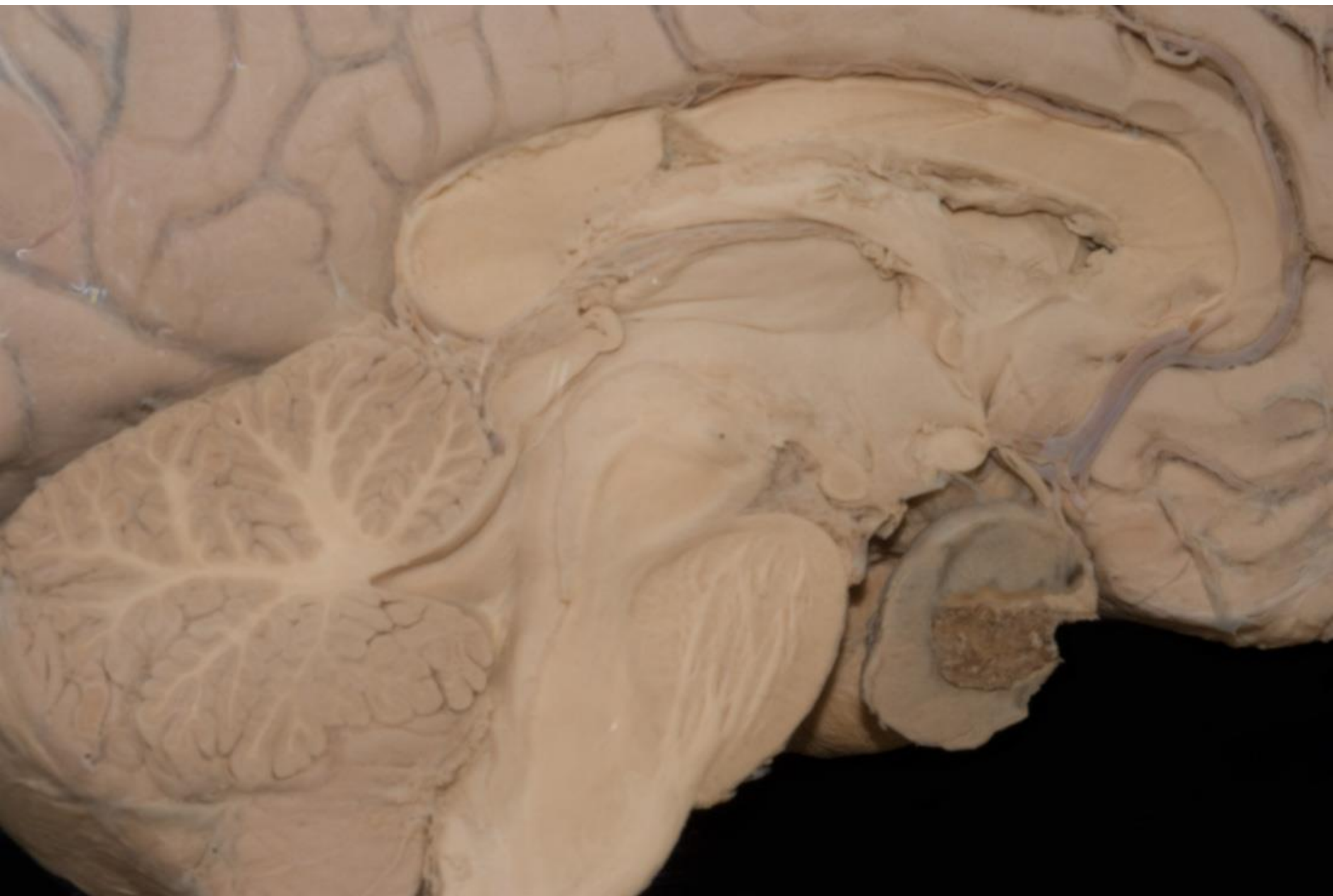


- **Case M12**
- **CLINICAL HISTORY:** This was a 19 year old male who had a history of frontal headaches for 6 years prior to his death. Six weeks prior to his admission, he became somewhat lethargic. Three weeks prior to admission, the patient had an episode of severe frontal headaches associated with loss of consciousness. For the 4 days prior to admission, the patient complained of nausea and vomiting, anorexia, photophobia, and dizziness when standing. At the time of admission, lumbar puncture revealed an opening pressure of 220 mm Hg with glucose 61 mg/dl. The patient had a cardiac arrest and died several days after admission. No neurologic diagnosis had been established.
- **GROSS PATHOLOGIC DESCRIPTION:** There is a large brain abscess in the right frontal lobe. At the time of autopsy, this abscess contained a thick, yellowish-gray exudate which contained multiple gram positive cocci on gram stain. A small daughter abscess is noted just adjacent to the mother abscess. The walls of both abscesses are quite well formed and microscopically are composed of fibrous tissue. Lateral displacement of ventricular system with subfalcine herniation of the cingulate gyrus is also noted. There is no transtentorial herniation.
- **DIAGNOSIS:** Abscess of the frontal lobe.
- **COMMENT:** The etiology of the cerebral abscess in this young man was undetermined. Presumably, it arose from an occult infection some months prior to the development of his cerebral symptoms, and the gross appearance of the abscess would support its chronicity. No evidence of infection was found in the rest of the body at the time of autopsy, and there were no cardiovascular malformations.

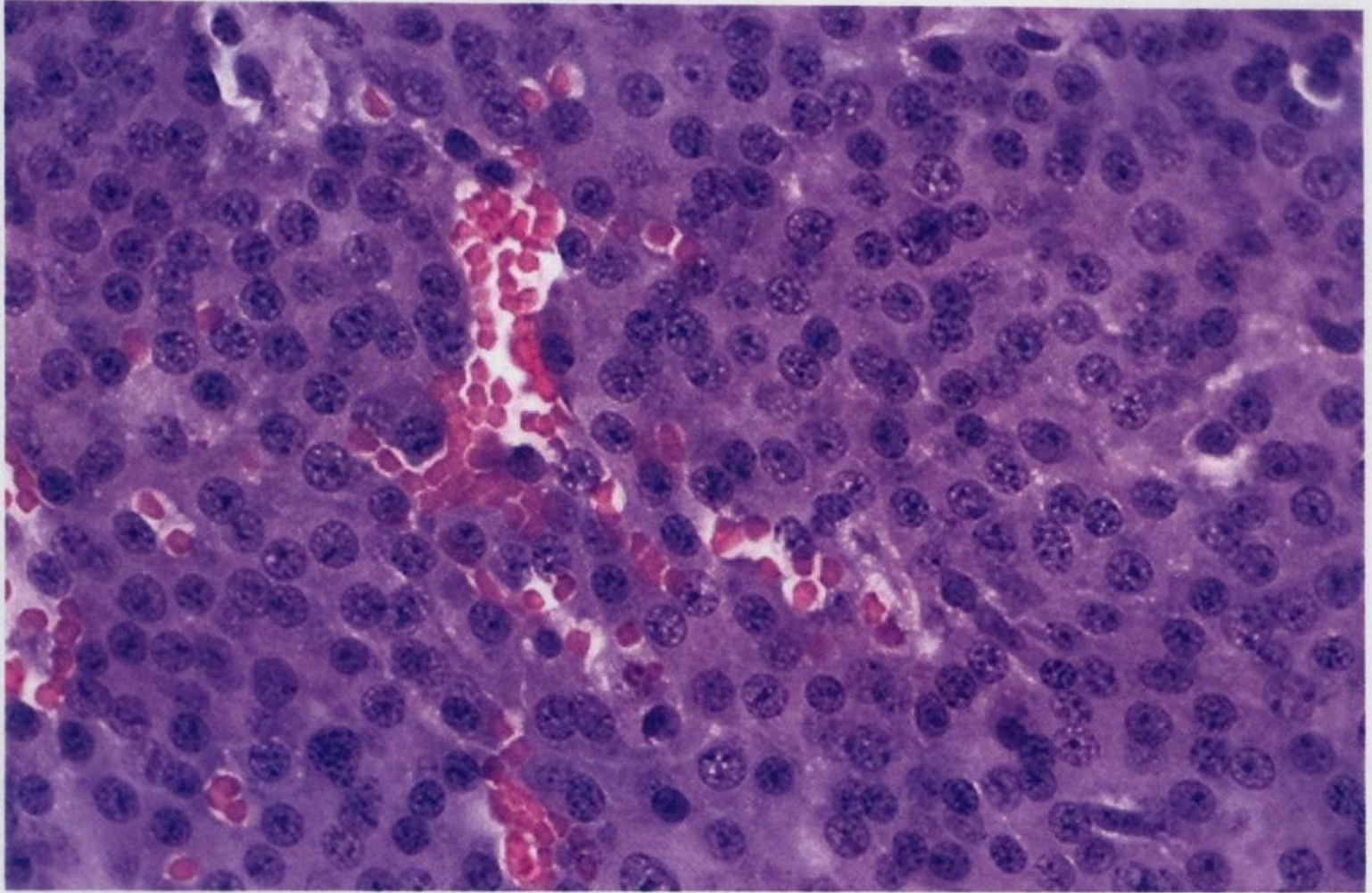




- **Case M13**
- **CLINICAL HISTORY:** This was a 66 year old male who was in good health until six months prior to death, at which time he complained of visual difficulties. These persisted and approximately two months prior to death, he came to the hospital. At that time neurological exam showed a bitemporal hemianopsia. Angiogram showed the anterior cerebral arteries to be displaced upward posteriorly and laterally by a mass in the sella turcica. Surgery was performed with a biopsy of the lesion. The patient received postoperative irradiation, but the patient expired five weeks after his operation.
- **DIAGNOSIS:** Pituitary adenoma



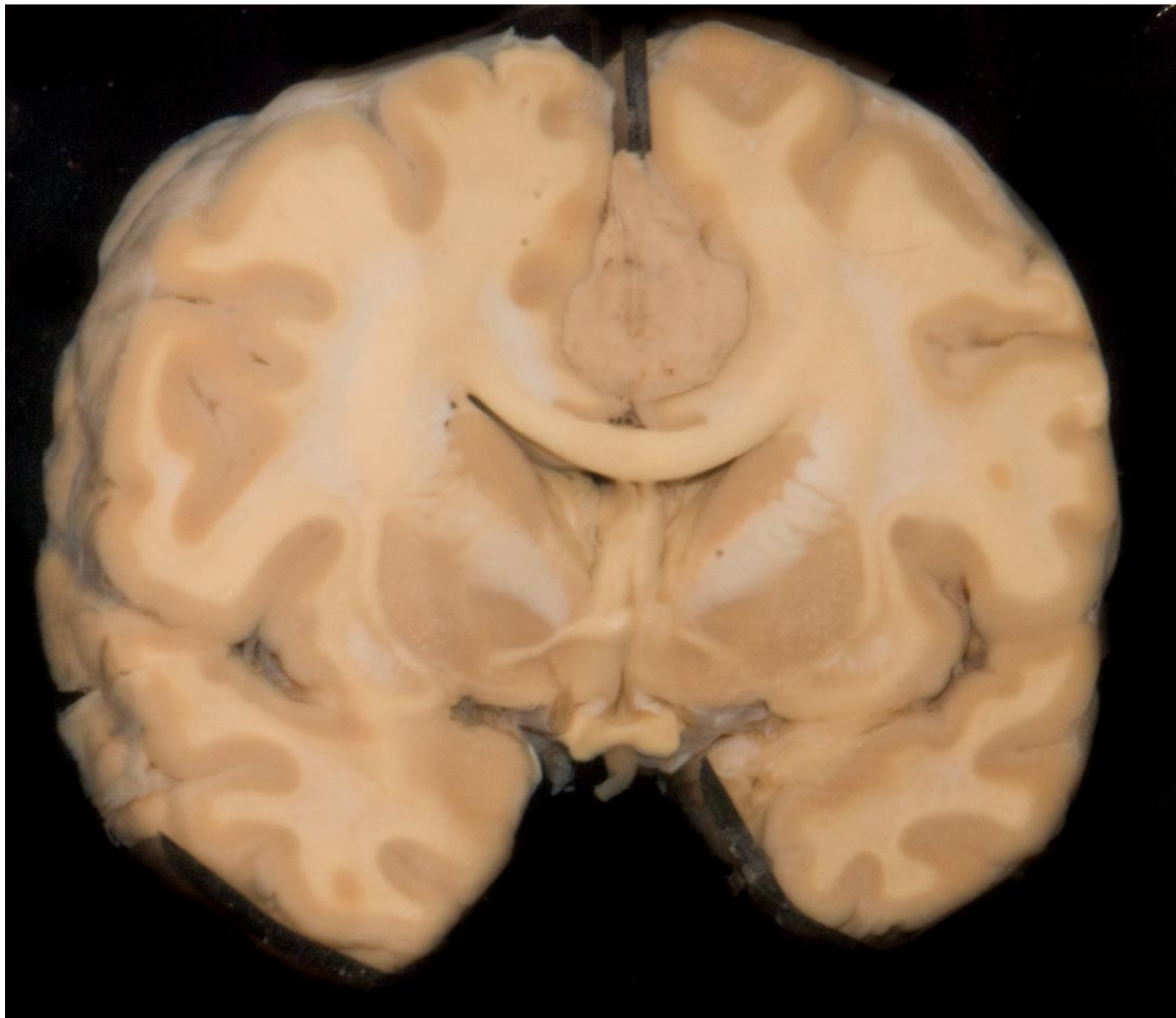


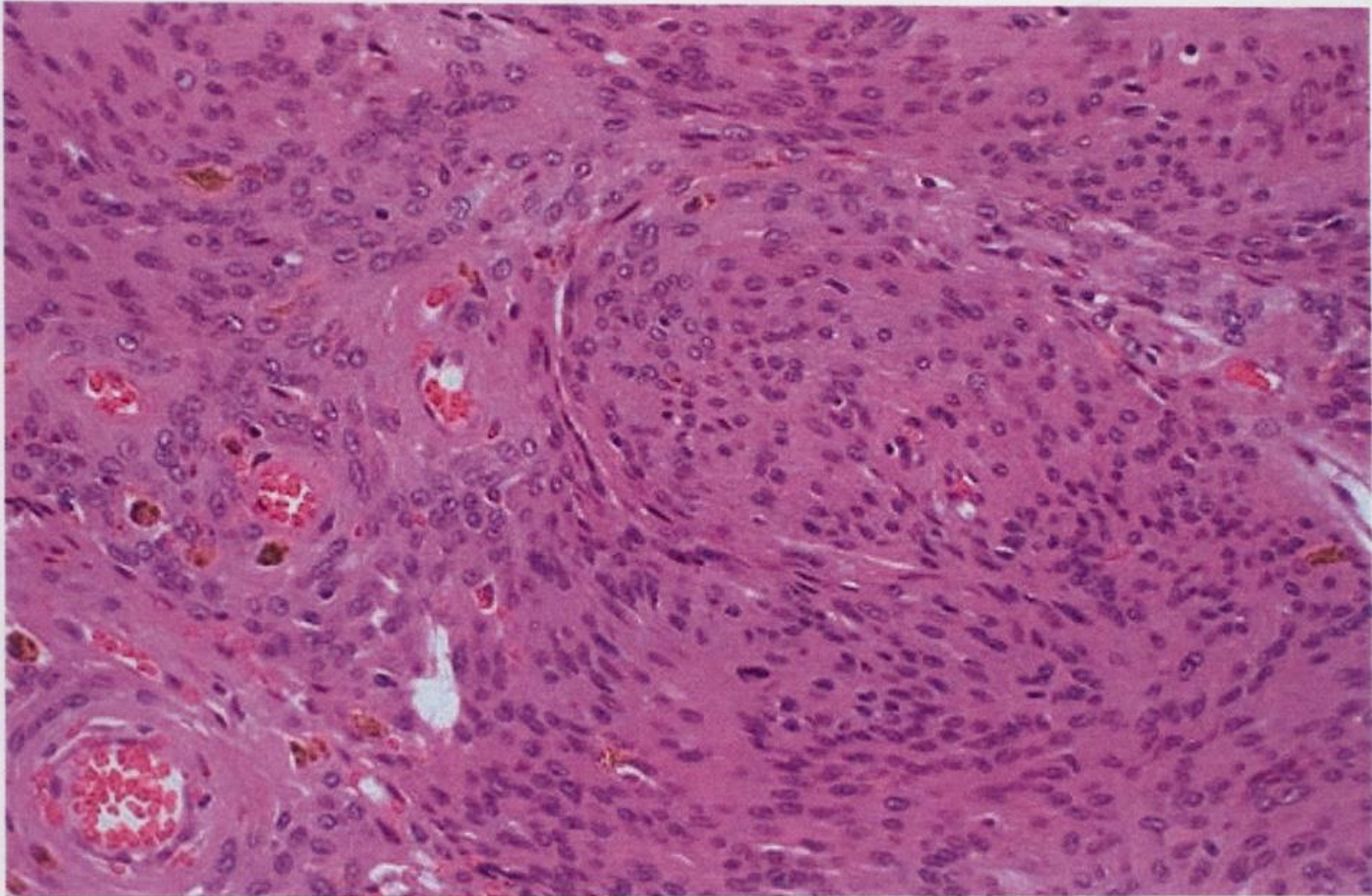


**Pituitary adenoma**

- **Case M14**
- **CLINICAL HISTORY:** This was a 60 year old female who had a several month history of syncopal episodes. In the first episode five months prior to her first admission, she had a sensation of “not being able to think” and subsequently blacking out. Jerking movements were described during that episode, but no incontinence, headache, or aura was described. Past history included a previous physical examination which showed weakness in the left arm and the legs and left calf tenderness approximately ten years prior to her admission. On the fourth hospital day she developed severe shortness of breath, bradycardia, and hypotension. She had an arrest and could not be resuscitated.
- **GROSS PATHOLOGIC DESCRIPTION:** This is a coronal section through the anterior temporal lobes. A large, firm mass which is whitish with reddish discoloration is seen arising from the dura over the right cerebral hemisphere, and this mass is projecting downward into the normal brain and compressing it, although not invading it. There is a shift of the midline structures to the right. In addition to this finding, a massive saddle embolus was found in the pulmonary arterial tree which was the cause of death.
- **DIAGNOSIS:** Meningioma, right parasagittal area







Meningioma

- **Case M15**
- **CLINICAL HISTORY:** This was a 41 year old white male who began to note involuntary jerking movements of the face and mouth 12 years prior to death. The disease progressed and he lost his job. He began to have problems with memory and developed psychiatric problems. During the last 3 years of life he was completely bed ridden with constant grimacing and jerking movements. He died of aspiration pneumonia.
- **GROSS PATHOLOGIC DESCRIPTION:** The brain weighed 1100 grams. This is a coronal section through the brain. There is symmetrical cortical atrophy with very severe atrophy and flattening of the caudate nuclei. The lateral ventricles are markedly dilated and the lateral walls have a concave rather than a convex contour as a result of the caudate nuclei atrophy. The putamen and globus pallidus are also extremely atrophic. Microscopically, there was marked loss of neurons and marked astrogliosis.
- **DIAGNOSIS:** Huntington disease

